

## REVIEW

# In vivo assessment of the biomechanical properties of the uterine cervix in pregnancy

Edoardo Mazza<sup>1\*</sup>, Miguel Parra-Saavedra<sup>2,3</sup>, Michael Bajka<sup>4</sup>, Eduard Gratacos<sup>2</sup>, Kypros Nicolaides<sup>5</sup> and Jan Deprest<sup>6</sup>

<sup>1</sup>Swiss Federal Institute of Technology, ETH Zurich, Zurich, Switzerland

<sup>2</sup>Maternal Fetal Medicine Department, ICGON, Hospital Clinic Universitat de Barcelona, Barcelona, Spain

<sup>3</sup>Maternal Fetal Unit, CEDIFETAL, Centro de Diagnostico de Ultrasonido e Imágenes, CEDIUL, Barranquilla, Colombia

<sup>4</sup>Department of Obstetrics and Gynecology, University Hospital of Zurich, Zurich, Switzerland

<sup>5</sup>King's College Hospital, London, UK

<sup>6</sup>KU Leuven, Flanders, Belgium

\*Correspondence to: Edoardo Mazza. E-mail: emazza@ethz.ch

## ABSTRACT

Measuring the stiffness of the cervix might be useful in the prediction of preterm delivery or successful induction of labor. For that purpose, a variety of methods for quantitative determination of physical properties of the pregnant cervix have been developed. Herein, we review studies on the clinical application of these new techniques. They are based on the quantification of mechanical, optical, or electrical properties associated with increased hydration and loss of organization in collagen structure. Quasi-static elastography determines relative values of stiffness; hence, it can identify differences in deformability. Quasi-static elastography unfortunately cannot quantify in absolute terms the stiffness of the cervix. Also, the current clinical studies did not demonstrate the ability to predict the time point of delivery. In contrast, measurement of maximum deformability of the cervix (e.g. quantified with the cervical consistency index) provided meaningful results, showing an increase in compliance with gestational age. These findings are consistent with aspiration measurements on the pregnant ectocervix, indicating a progressive decrease of stiffness along gestation. Cervical consistency index and aspiration measurements therefore represent promising techniques for quantitative assessment of the biomechanical properties of the cervix. © 2013 John Wiley & Sons, Ltd.

Funding sources: None

Conflicts of interest: None declared

## INTRODUCTION

Effective, reliable and reproducible methods for quantitative assessment of the biomechanical properties of the uterine cervix may be used to predict the success of induction of labor or the increased risk of spontaneous premature delivery. A stiff cervix might indicate failure of induction of labor, and a soft cervix might correlate with higher risk of preterm delivery. For the latter, identification of patients at risk is an essential prerequisite to take measures to prevent it from happening or to timely reduce its consequences.<sup>1</sup> Cervical length,<sup>2,3</sup> maternal factors (e.g. age, height, and obstetric history),<sup>4–6</sup> and biomarkers (mainly, fetal fibronectin)<sup>7</sup> allow the calculation of the risk for premature delivery. Biomechanical cervical assessment can also be used for this purpose, although that is not an established methodology yet. This is in part due to lack of adequate tools as well as a paucity of clinical studies demonstrating its relevance, as illustrated in this article.

From a biomechanical viewpoint, the uterus in pregnancy can be considered as a container with internal pressure causing mechanical loading of its wall. The cervical orifice

represents a discontinuity of the uterine wall and thus a structural weak point. The cervix functionally can be seen as a local increase of the wall thickness of the pressurized container, thus reinforcing the region adjacent to the orifice and avoiding its dilatation. Loading of the cervix is the result of the balance between opening forces, that is, internal uterine pressure, and the external forces that keep the cervix closed, that is, the reaction forces of the lower abdomen and pelvic floor. The cervical response to this state of mechanical loading, that is, its subsequent deformation, opening, and shortening, depends on the biomechanical properties of cervical tissue.

In mechanics, the properties of a tissue are defined on the basis of the force required to generate a specific deformation. Deformations in an organ can be quantified from a comparison between a reference state (unloaded configuration, i.e. zero force state) and its shape after application of a given force. A material line element is the line segment connecting two adjacent points in a material. Change in length of any material line element can be described as the percentage increase (*tensile strain*) or decrease (*compressive strain*) in line segment length.

The force required to obtain a certain level of strain depends on the mechanical properties of the tissue, as well as on the geometrical dimensions of the organ; that is, for a larger area of force application, the required force for the same strain is higher. For this reason, tissue properties are described as a relationship between *strain* and *stress*, that is, a specific displacement (from initial length) versus a specific force (per unit area). Stress–strain curves characterize the mechanical behavior of a tissue. A simplified representation of this relationship describes the stress as proportional to strain, and the slope of this linear relationship is called *Young's modulus*. Stiffer tissue has a larger Young's or elasticity modulus: They will need more force or stress for a given relative displacement or strain. Determination of Young's modulus or other parameters characterizing a more complex stress–strain curve (such as creep compliance, relaxation modulus, or strain energy coefficients) is the objective of a biomechanical characterization of a biological tissue.

When mechanical loading is sufficiently high or the stiffness of the cervix is sufficiently low, the cervix yields. Opening starts from the internal os, thus leading to progressive shortening and final dilatation.<sup>8</sup> At the time of birth, the circumference of the cervix increases multiple times to allow the passage of the child. However, only few hours after delivery, the cervix has recovered its consistency and closed shape.<sup>8</sup> Therefore, changes in the cervix, either in physiologic or in pathologic circumstances, must be dramatic, yet they remain poorly defined.

Changes in biomechanical properties of cervical tissue are related to modifications of the microstructure. Histological and biochemical studies on animal tissue<sup>9–13</sup> and human cervical biopsies<sup>14–19</sup> have provided insights in modifications of the extracellular matrix of the cervix in pregnancy and delivery. As reviewed by Timmons *et al.*,<sup>20</sup> remodeling consists of changes in synthesis, assembly, and degradation of collagen fibers affecting its distribution, cross-links density, and organization. These modifications are related to changes in the composition of glycosaminoglycans and are associated with increased tissue hydration, increased viscous behavior, and reduced stiffness in the course of pregnancy. In normal pregnancy, the increased deformability of the pregnant cervix does not result in morphological changes until the third trimester. Two recent studies provide direct evidence of a progressive decrease in stiffness of the cervix along gestation. Parra-Saavedra *et al.*<sup>21</sup> documented a linear increase in deformability of the cervix (i.e. a reduction of the antero-posterior diameter at the midpoint of the cervical length upon application of compressive force) with gestational age. Along the same lines, Badir *et al.*<sup>22</sup> demonstrated a continuous decrease in stiffness of the ectocervix. Both studies show that cervical tissue softens *progressively* during gestation whereas cervical length reduces *only* in the third trimester.

Being a necessary but not sufficient condition for morphological changes such as cervical opening and shortening, measuring the microstructural disorganization and increased water content affecting the consistency of cervical tissue might offer an opportunity for early detection of enhanced risk of premature delivery or for prediction of failed induction of labor. The potential added value of appropriate measurement of

biomechanical changes has motivated researchers to develop and evaluate the effectiveness of measuring methods of these biomechanical properties of the cervix during pregnancy. Feltovich *et al.*<sup>23</sup> discuss a wide range of methods recently proposed to assess the pregnant cervix. Preclinical experiments have shown that techniques to measure propagation velocity of low frequency elastic waves (i.e. shear wave speed)<sup>24</sup> and quantitative analysis of the microstructure (Raman spectroscopy<sup>25</sup> and backscattered power loss)<sup>19,26</sup> are promising for future clinical use. Herein, we aimed to review those methods that have already been applied *in vivo* on the human cervix hence are closer to clinical application. Table 1 displays the clinical studies we identified, usually performed on patients throughout gestation or at the time of induction of labor.

## ELASTOGRAPHY

Elastography quantitatively analyzes tissue deformability.<sup>27,28</sup> In quasi-static ultrasound elastography, a force is applied to induce motion of an organ. The corresponding displacement field is quantified using image analysis algorithms able to track the position of a large number of points at any time during the motion. If a region within the organ would behave as a perfectly rigid body, the distance between the points of this region would not change during the motion. Conversely, a very soft region within the organ would display large changes in distance between the points, that is, large strains. On the basis of the distribution of strain within the organ, the local tissue deformability is assessed, typically aiming at detecting regions with low strains, that is, higher stiffness (higher Young's modulus) as compared with its surroundings. These methods have first been used to assess tissues that are suspected to have areas of malignancy. The deformation field within the organ is quantified during slow deformation cycles, normally induced by pushing and retracting the handheld ultrasound probe. The result is displayed in the form of a color map (called elastogram) indicating differences between soft and hard regions within the deformed organ.<sup>29</sup> Most notorious applications of this concept are in the field of breast cancer and cardiovascular diseases.<sup>30</sup>

More recently, elastography has also been applied to transvaginal ultrasound of the cervix.<sup>31–36</sup> Thomas<sup>31</sup> determined an 'elasticity tissue quotient', which was based on the ratio of observed colors in the elastograms. The findings were reported to be correlated to maternal age yet, not gestational age. With a similar technique, Yamaguchi *et al.*<sup>32</sup> studied the properties of the anterior cervical lip. 'Slight pressure' was exerted on the portio to induce deformations. Although they mention that 'the stiffness of the cervix changes during gestation', no actual data are reported. Khalil *et al.* also did a pilot study on 12 pregnant women at different gestational ages<sup>35</sup> and compared strains in the lower, middle, and upper cervix, again using 'light repetitive compression'. Deformations decreased from the external to the internal os, and they concluded that the 'elasticity of the cervix increases toward portio'. However, as they note in their discussion, the magnitude of the force applied on the external part reduces in magnitude when transmitted through the organ. Reduced deformation is thus likely to be the result of a smaller force

Table 1 Overview of clinical studies that characterized the biomechanical properties of the cervix

Ref.	Aim	Method	n	Study population	Outcome
Swiatkowska-Freund and Preis <sup>33</sup>	IOL	Elastography	29	29 women prior to IOL	Larger strain in internal os correlates with successful induction. No correlation with Bishop score nor cervical length.
O'Connell <i>et al.</i> <sup>53</sup>	IOL	Electrical impedance	86	86 women prior to IOL	Resistivity significantly lower in patients successfully induced.
O'Connell <i>et al.</i> <sup>54</sup>	IOL	Electrical impedance	205	205 women prior to IOL	Resistivity lower in case of vaginal delivery and higher when syntocinon required.
Maul <i>et al.</i> <sup>51</sup>	IOL, SPD	Collascope: light-induced fluorescence (LIF)	40	Nonpregnant controls and pregnant (21–39 weeks.) prior to IOL. Including 10 pregnant with cervical insufficiency	LIF decreases with gestational age can predict delivery within 24 h; is decreased after prostaglandin administration. LIF very low in cases of cervical insufficiency.
Schlembach <i>et al.</i> <sup>52</sup>	IOL, SPD	Collascope: light-induced fluorescence (LIF)	40	Nonpregnant controls and pregnant (21–39 weeks.) prior to IOL. Including 10 pregnant with cervical insufficiency	LIF decreases with gestational age can predict delivery within 24 h; is decreased after prostaglandin administration. LIF very low in cases of cervical insufficiency.
Parre-Saavedra <i>et al.</i> <sup>21</sup>	SPD	Maximum deformability: cervical consistency index	1031	Pregnant women (5–36 weeks.)	Deformability increases linearly with gestational age. CCI is a better predictor of SPD than cervical length
McFarlin <i>et al.</i> <sup>47</sup>	SPD	Ultrasound attenuation	40	Pregnant women (10–41 weeks.)	Weak correlation between attenuation and gestational age Predictive potential claimed
Tekesin <i>et al.</i> <sup>49</sup>	SPD	US gray-level histogram	117	Pregnant with preterm labor (24–34 weeks.)	Mean gray value improves prediction of SPD if combined with fibronectin and cervical length.
Thomas <sup>31</sup>	Meih	Elastography		Not described	Age-related differences in cervical strain. No correlation with gestational age.
Yamaguchi <i>et al.</i> <sup>32</sup>	Meih	Elastography		Not described	Differences in deformability detected depending on gestational age.
Molina <i>et al.</i> <sup>34</sup>	Meih	Elastography	112	Pregnant women (12–40 weeks.)	Ectocervix softer than endocervix. High reproducibility
Khalil <i>et al.</i> <sup>35</sup>	Meih	Elastography	12	Pregnant women (15–33 weeks.)	No correlation of strain with gestational age. Portio softer than rest of cervix.

(Continues)

Table 1 (Continued)

Ref.	Aim	Method	n	Study population	Outcome
Hernandez-Andrade <i>et al.</i> <sup>36</sup>	Meih	Elastography	262	Pregnant women (8–40 weeks.)	Weak correlation of strain with gestational age. Cervical canal and ectocervix softer than internal os.
Fruscalzo <i>et al.</i> <sup>38</sup>	Meih	Maximum deformability	21	Pregnant women at term (n = 11) or at 19 weeks (n = 10)	Good reproducibility of measurements. Maximum deformability higher at term compared with midgestation.
Fruscalzo <i>et al.</i> <sup>39</sup>	Meih	Aspiration	100	50 nonpregnant controls, 50 pregnant women (8–40 weeks.)	Stiffness of ectocervix reduces with gestational age.
Badir <i>et al.</i> <sup>22</sup>	Meih	US graylevel histogram	214	Pregnant women (27–30 weeks.)	Gray-level difference between anterior and posterior cervix correlates with consistency by digital palpation
Kuwata <i>et al.</i> <sup>48</sup>	Meih	Electrical Impedance	140	50 nonpregnant controls and 90 pregnant women	Impedance decreases in first trimester and increases in third trimester.
Gandhi <i>et al.</i> <sup>55</sup>	Meih	Near infrared spectroscopy	13	Pregnant women (6–41 weeks.)	Weak correlation between optical properties and gestational age.

IOI, induction of labor; SPD, spontaneous premature delivery; Meih, methodologic; that is, feasibility and reproducibility; CCI, cervical consistency index. Last column: principal findings.

rather than smaller stiffness. Molina *et al.*<sup>34</sup> evaluated 112 women at different gestational ages. They applied loading cycles with the ultrasound probe according to an indicator of compression magnitude provided by their ultrasound system.<sup>37</sup> Although no force sensor is present in the equipment, the level of compression can be standardized to achieve a predefined magnitude of motion within the observed region. This approach resulted in a high level of inter-observer and intra-observer reproducibility. Larger deformability was observed in the external and superior part of the cervix when compared with the internal and inferior part, which, again, might reflect the magnitude of the force transmitted through the tissue. The authors did not report any correlation between elastographic measurements and gestational age.

All aforementioned studies were methodological in nature, but predictive studies were also performed. Swiatkowska-Freund and Preis<sup>33</sup> used elastography for predicting the success of induction of labor in 29 patients by the so-called elastography index. This is a five-step scale based on the local color of the elastogram in each region of the cervix. Elastography was performed without movement of the transducer toward the cervix, and deformations only resulted from physiological displacement related to breathing and arterial pulsation. The internal os was significantly softer if labor started within 9 h of oxytocin infusion. The elastography index of the external os and of the middle part of the cervical canal was not different between the two groups. No correlation was found between the elasticity index of the cervix and the Bishop score or cervical length.

Lately, Hernandez-Andrade *et al.*<sup>36</sup> performed 'semiquantitative ultrasound elastography' to determine cervical stiffness in pregnancy. Strain in the whole cervix and in the cervical canal was measured in sagittal and cross-sectional planes. Two hundred sixty-two patients were evaluated between 8 and 40 weeks. The region of the cervical canal was shown to be softer, and in line with the literature,<sup>34,35</sup> the outer region displayed larger strains as compared with the internal region. Similar to the approach of Molina *et al.*,<sup>34</sup> the intensity of the compression cycles was selected to reach a specific range within the 'pressure bar displayed on the ultrasound monitor'. Only a weak correlation was found between tissue strain and gestational age (Figure 1). Although the authors claim that their results show 'a

continuous reduction in cervical stiffness with decreasing cervical length and advancing gestational age', their findings being displayed in Figure 1 would rather show that cervical consistency does not change significantly along gestation.

Elastograms 'are often incorrectly interpreted as a direct visualization of the material tissue stiffness'.<sup>29</sup> This problem was recognized by most researchers, who interpreted their findings as measures of deformation, not stiffness. As a consequence, methods were sought for standardizing the magnitude of the compressive force applied to the cervix. In fact, if the same force is applied, a softer cervix will deform more as compared with a stiffer cervix, thus providing objective information on tissue stiffness. However, no control over the level of force in the tissue can in reality be obtained, because none of the used elastography system includes a force sensor. Thus, no information on the level of applied force is provided by the 'pressure bar displayed on the ultrasound monitor'.<sup>36</sup> Indication of required levels of tissue compression is based on kinematical information only (strain or displacement field), aiming at a deformation state, which enables meaningful extraction of local strain values. For this reason, the elastograms obtained in all aforementioned studies enable a relative comparison of the consistency of different regions of the cervix but cannot be used to determine absolute values of tissue stiffness. In fact, the original aim was to discriminate between stiff inclusions in a homogeneously soft and otherwise healthy organ and not to provide absolute values of tissues mechanical properties.<sup>28</sup> It is therefore not surprising that the aforementioned studies could determine regional differences in stiffness but no correlation between overall strain level and gestational age. Because of the anatomical features of the region considered, the application on the cervix was additionally affected by an inherent larger deformation in the region closer to the transducer, which was exposed to larger stresses.

As shown in the study of Swiatkowska-Freund and Preis,<sup>33</sup> elastography might help identifying cervixes of women who will have a successful induction of labor by quantifying the deformability of the internal os relative to the rest of the organ. Unfortunately, this method is unlikely to provide useful information for the diagnosis of higher risk of premature delivery.

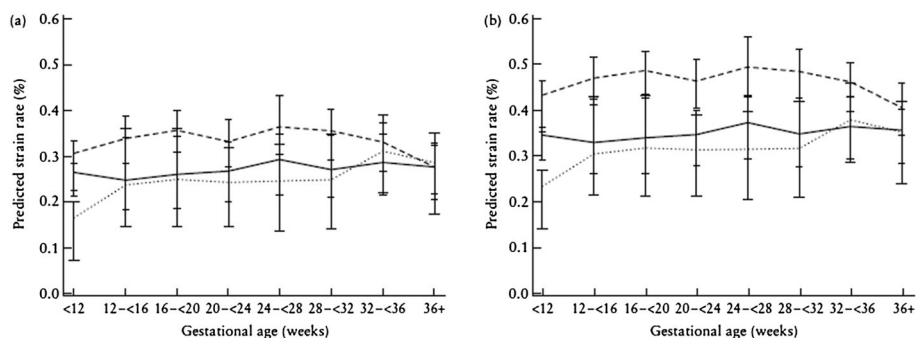


Figure 1 From the study of Hernandez-Andrade *et al.*,<sup>36</sup> with permission from John Wiley and Sons. Gestational age dependence of cervical tissue strain, for complete cervix (left) and cervical canal (right). Each curve refers to different ultrasound views (sagittal, transverse internal os, and transverse external os)

## MAXIMUM TISSUE DEFORMABILITY

Two groups characterized the deformability of the cervix using ultrasound but from a different perspective. Parra-Saavedra *et al.*<sup>21</sup> and later Fruscalzo *et al.*<sup>38,39</sup> used real-time ultrasound visualization of the sagittal plane of the cervix and manually compressed the cervix with the ultrasound transducer until no further deformation could be observed in the region of interest. This determines the *level of maximum tissue deformability*. This is performed to overcome the problem of the inability to measure the force used when doing elastography<sup>40</sup>: ‘even if it is not measurable, the force can be standardized by choosing to compress maximally the anterior cervical lip...’. Although this still is a kind of elastography, it utilizes a different criterion for the application of the compressive force and a different read out (maximum strain).

Parra-Saavedra *et al.* used this in a cross-sectional study on >1000 pregnant women. Significant efforts were made to standardize next to the maximum compression also the extraction of geometrical data, thus enabling reproducible determination of what is called cervical consistency index (CCI). This quantitative measure corresponds to the ratio between the anteroposterior diameter at maximum compression and the diameter at rest. A CCI of 0.5 for a cervix means that the cervical diameter is reduced to half of its initial value. This would be a soft cervix whereas a cervix with CCI = 1 would be very stiff as it cannot be deformed or squeezed at all. Figure 2 displays the data from the study of Parra-Saavedra *et al.*<sup>21</sup> The CCI linearly decreases, or the cervical deformability increases with gestational age. This is in agreement with findings in microstructural and histological studies but in contrast to the expectations described in the study of Word *et al.*<sup>8</sup> and with the findings of Hernandez-Andrade *et al.*<sup>36</sup> The women ultimately delivering preterm had a significantly lower CCI. Moreover, the CCI was better predictive than cervical length measurements.<sup>21</sup>

Independently, Fruscalzo *et al.*<sup>38,39</sup> developed a similar protocol, in which strain values are determined in the anterior cervix after achieving ‘maximal compression of the anterior

portion of cervical tissue’. In 10, respectively 11 pregnant cervixes were measured at 20 and 39 weeks of gestation, with a low inter-observer variability. Values of compressive strain ( $\varepsilon$ ) in the region of maximum deformation are reported, that is, average  $\varepsilon = 33\%$  in week 20<sup>38</sup> and average  $\varepsilon = 51\%$  in week 39,<sup>39</sup> confirming the data of Parra-Saavedra *et al.* that the cervix can be more deformed later in gestation. Compressive strain data can be directly converted to corresponding values of the CCI of Parra-Saavedra *et al.*:  $CCI = 1 - \varepsilon$ . Figure 2 compares the data of both studies. They agree to a good extent, despite the differences in the measurement method. In fact, Parra-Saavedra *et al.* applied a compressive force till no more deformation of the whole cervix could be detected, whereas Fruscalzo *et al.* limited the force to the maximum deformation of the anterior part, which was achieved at lower forces than having the compression of the complete cervix as endpoint. This might explain the fact that the data of Fruscalzo *et al.* demonstrate a somewhat lower deformability (higher CCI values) as compared with the data of Parra-Saavedra *et al.*

## ASPIRATION

The aspiration method was developed to determine the *in vivo* stress–strain curve of soft tissues in human organs. This method has been initially used on the liver<sup>41,42</sup> to document changes related to various pathologies. It was later applied to the cervix.<sup>43,44</sup> The device measures the vacuum (negative pressure) required to displace the tissue for a given distance. Measurements on the ectocervix were performed such that the (negative) pressure, named ‘ $p_{cl}$ ’, needed to displace the tissue up to 4 mm is recorded. Lower values of  $p_{cl}$  correspond to lower stiffness.<sup>45</sup> In a series of 448 measurements in 50 pregnant women throughout pregnancy and on nonpregnant subjects (reference,  $n = 50$ ),<sup>22</sup> stiffness in early pregnancy (first trimester) was significantly lower than in nonpregnant individuals. The force needed to deform the cervix ( $p_{cl}$ ) steadily decreased during gestation. After delivery (average 6 weeks postpartum), consistency recovers to the level of early pregnancy.

During pregnancy, the stiffness of the ectocervical tissue drops by a factor 5. Data analysis allows determining corresponding stress–strain curves,<sup>45</sup> which are in line with observations made by *ex vivo* measurements.<sup>46</sup> A fitting curve is determined for the mean  $p_{cl}$  values, as a function of gestation (the equation is indicated in Figure 3). The pressure values are directly proportional to tissue stiffness. Thus, the stiffness of the cervix might be expected to drop according to the same time function. On the basis of this assumption, the expected time course of the CCI can be estimated, considering that the deformability of the tissue is a measure of tissue compliance, that is, the inverse of stiffness:  $(1 - CCI) = \varepsilon \sim 1/p_{cl}$ . The corresponding prediction of CCI evolution is shown in Figure 2 and demonstrates a general qualitative agreement between observations from aspiration measurements and CCI.

## OTHER TECHNIQUES

Techniques addressing quantitative determination of modification of physical properties associated with changes in the extracellular matrix of cervical tissue were recently proposed, and some were applied *in vivo*. Changes leading to progressive

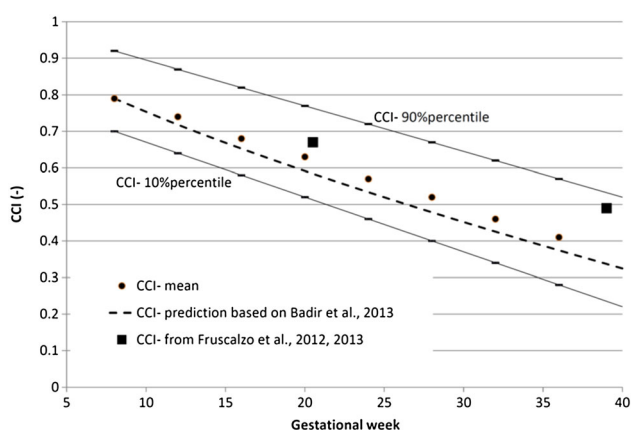


Figure 2 Cervical consistency index (CCI): lines of 10% and 90% percentiles and data for 50% percentile from the study of Parra-Saavedra *et al.*<sup>21</sup> Corresponding observations from the study of Fruscalzo *et al.*<sup>38,39</sup> are reported as squares. The prediction of evolution of CCI over gestational age, based on the aspiration measurements,<sup>22</sup> is reported as dotted line

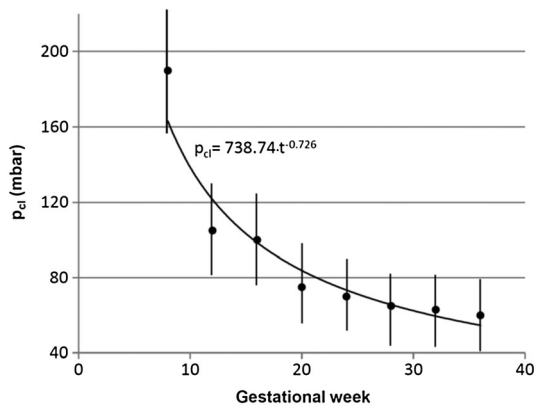


Figure 3 Suction pressure from aspiration measurements at different gestational ages. Mean values and standard deviations are reported on the basis of the data from the study of Badir *et al.*<sup>22</sup> A power law trend line is determined for the dependence of suction pressure  $p_{cl}$  on gestational time  $t$

softening in pregnancy and ripening at term are related to microstructural modifications mainly identified as an increased hydration and loss of organization in collagen structure.<sup>9</sup> The ultrasound signal amplitude decreases with distance from the transducer. This effect is called 'attenuation' and depends on the mechanical properties of the tissue. Measurements were performed on the cervix of 40 pregnant women, and mean ultrasound signal amplitude decay was determined.<sup>47</sup> Weak correlations were found indicating a decrease in attenuation with gestational age. The study concludes suggesting acquisition of larger number of measurements for an evaluation of diagnostic relevance in determining risk of premature delivery.

Evaluation of echogenic properties of cervical tissue using ultrasound gray-level histograms was proposed in the study of Kuwata *et al.*<sup>48</sup> Two hundred fourteen women at 27–30 weeks of gestation were investigated, and a positive correlation was found between anterior–posterior gray-level difference and cervical consistency determined by digital palpation. Similarly, Tekesin *et al.*<sup>49</sup> have shown that gray-level evaluation combined with a fetal fibronectin test improves the prediction of preterm delivery. In their latest work,<sup>50</sup> the group concluded that the intra-observer and inter-observer variability of quantitative ultrasound characterization is poor and that the method should not be applied in clinical practice.

The light-induced fluorescence of pyridinoline, which is one of the major cross-link elements in collagen fibrils, has been measured in cervical tissue of animals and humans using the collascope.<sup>51,52</sup> The instrument consists of a probe delivering a light signal to the cervical tissue and carrying back the fluorescent light emission, which is then analyzed in a computer system to obtain a fluorescence spectrum. The fluorescence intensity dropped significantly after week 25, indicating a progressive loss of cross-link density, and was predictive of delivery within 24 h. Prior to 25 weeks, no differences could be seen with respect to the nonpregnant cervix, so this method seems not sensitive to microstructural changes occurring early in pregnancy.

Physical properties are affected by the level of water content in the extracellular matrix. In particular, higher hydration reduces the electrical resistivity and increases light absorption. For determination of electrical resistivity, electrodes are applied on the cervix and measure the voltage required to obtain a specific current through the tissue. Resistivity measurements<sup>53</sup> demonstrated lower values for the pregnant cervix. Later, the same group<sup>54</sup> performed a study with 86 pregnant women prior to induction of labor. They measured a significantly lower resistivity (higher hydration) in patients with a 'favorable cervix' (Bishop score  $\geq 5$ ). Impedance spectroscopy measurements in 50 nonpregnant and 90 pregnant women were performed by Gandhi *et al.*<sup>55</sup> Hydration increases lead to a reduction of impedance at the beginning of gestation. Surprisingly, this group reported higher values in the third trimester, with impedance data larger than those of the nonpregnant group. They attributed that to 'the increased cellular and collagen (extracellular matrix) content'. Jokhi *et al.*<sup>56</sup> measured cervical electrical resistivity in 205 pregnant women before induction of labor and compared it with the Bishop score. For one specific electrode arrangement, cervical resistivity was predictive of vaginal delivery and was significantly higher in women who required syntocinon augmentation of labor. Overall, the correlations were weak, so the authors conclude that 'the device performance did not achieve sufficient accuracy to enable employing this tool for clinical purposes at present'.

Frequency domain near infrared spectroscopy was applied by Hornung *et al.*<sup>57</sup> to detect changes in light absorption and scattering coefficients. These optical properties depend on the microstructure of the tissues, with water increasing absorption and fibrous components increasing light scatter. In 13 pregnant women, only a weak correlation was observed between optical properties and gestational age.

## DISCUSSION AND CONCLUSIONS

There is intensive research going on to characterize the biomechanical and microstructural properties of the cervix during pregnancy. Current elastography-based methodologies fall short for measuring the biomechanical properties of the cervix, primarily because it is difficult to standardize or measure the applied force. The currently available clinical studies failed to demonstrate a change over the duration of pregnancy, whereas one expects such change based on microstructural studies or when using other methods.<sup>21,22,38,39</sup>

Conversely, elastography does detect regional differences in strain distribution. It is actually for that exact reason that elastography works well to identify and localize cervical cancer, which is a local process.<sup>58</sup> Over time, this limitation may be overcome by application of so-called dynamic elastography (measuring shear wave speed), which has not been used *in vivo* so far.<sup>23,59</sup>

Ultrasound measurement of the maximum deformability of the cervix<sup>21,38,39</sup> in contrast has been shown to be more successful. This approach has similar drawbacks as elastography methods in that it lacks a direct measurement of the applied force and includes a certain degree of subjectivity. However, the criterion adopted (compression until maximum anterior–

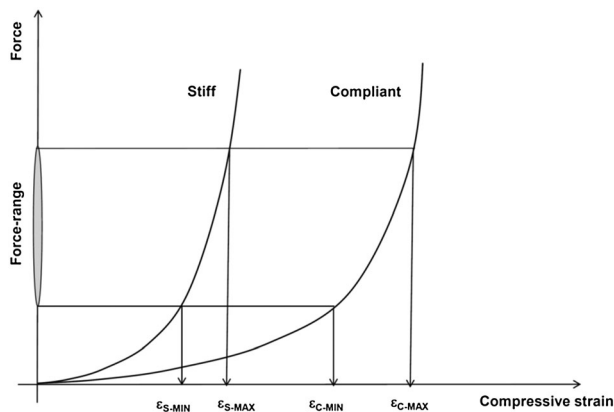


Figure 4 Qualitative representation of force–deformation relationship for a stiff and for a compliant cervix. The levels of measured minimum and maximum strain for each curve correspond to a minimum and maximum applied force (see indicated force range)

posterior deformation) allowed achieving high levels of intra-observer and inter-observer reproducibility<sup>21,38,39</sup> and demonstrated increased compliance of the cervix along gestation. From a mechanical point of view, this is logic, because the relationship between global tissue deformation and applied force is expected to be highly nonlinear (as opposed to the oversimplified view of the tissue to respond according to a linear stress–strain curve, i. e. according to the value of its Young's modulus). The nonlinear force–deformation relationship is qualitatively represented in Figure 4 and shows a slower progression of strain for an increased force at larger strain levels. Note that these curves qualitatively represent the expected nonlinear response of a stiff and a compliant cervix, but no corresponding measurements exist. Even with the indicated large variability in the applied force level (see 'Force-range' in Figure 4), the measured strain for the stiff cervix (between  $\epsilon_{S-MIN}$  and  $\epsilon_{S-MAX}$ ) is much lower than the one for the compliant cervix (between  $\epsilon_{C-MIN}$  and  $\epsilon_{C-MAX}$ ). Note that at larger force level, yielding of upper cervix and pelvic organs leads to cervix dislocation rather than deformation, thus inherently limiting the maximum force that can be applied on the cervix.

## REFERENCES

- Hassan SS, Romero R, Vidyadhari D, *et al.* Vaginal progesterone reduces the rate of preterm birth in women with a sonographic short cervix: a multicenter randomized double-blind, placebo controlled trial. *Ultrasound Obstet Gynecol* 2011;38:18–31.
- Celik E, To MS, Gajewska K, *et al.* Cervical length and obstetric history predict spontaneous preterm birth: development and validation of a model to provide individualized risk assessment. *Ultrasound Obstet Gynecol* 2008;31:549–54.
- To MS, Skentou, CA, Royston P, Yu, CKH. Prediction of patient-specific risk of early preterm delivery using maternal history and sonographic measurement of cervical length: a population-based prospective study. *Ultrasound Obstet Gynecol* 2006;27:362–7.
- Beta J, Akolekar R, Ventura W, *et al.* Prediction of spontaneous preterm delivery from maternal factors, obstetric history and placental perfusion and function at 11–13 weeks. *Prenat Diagn* 2011;31:75–83.
- Souka AP, Papastefanou I, Michalitsi V, *et al.* A predictive model of short cervix at 20 and 24 weeks using first-trimester cervical length measurement and maternal history. *Prenat Diagn* 2011;31:202–6.
- Greco EL, Lange A, Ushakov F, *et al.* Prediction of spontaneous preterm delivery from endocervical length at 11 to 13 weeks. *Prenat Diagn* 2011;31:84–9.
- Defranco EA, Lewis DF, Odibo AO. Improving the screening accuracy for preterm labor: is the combination of fetal fibronectin and cervical length in symptomatic patients a useful predictor of preterm birth? A systematic review. *Am J Obstet Gynecology* 2013;208:233.e1–6.
- Word RA, Li XH, Hnat M, Carrick K. Dynamics of cervical remodeling during pregnancy and parturition: mechanisms and current concepts. *Semin Reprod Med* 2007;25:69–79.
- Read C, Word R, Ruscheinsky M, *et al.* Cervical remodeling during pregnancy and parturition: molecular characterization of the softening phase in mice. *J Reprod Fertil* 2007;134:327–40.

The aspiration measurements<sup>22</sup> provided evidence of progressive softening of the ectocervix in pregnancy, with an initial higher decrease in stiffness in the first two trimesters and subsequent slower loss of stiffness in the third trimester. Despite the fact that this biomechanical measurement is confined to the external surface of the ectocervix, the observed time course of the decrease in stiffness parallels the compliance changes in the entire cervix described by Parra-Saavedra *et al.*<sup>21</sup>

Current elastography techniques cannot measure biomechanical properties of the whole cervix. Introducing a force sensor in the elastography equipment might provide an objective procedure to quantify cervical stiffness. Alternatively, compressing the cervix to achieve its maximum deformation allowed determining the level of tissue compliance. CCI and aspiration method demonstrated that cervical compliance increases and stiffness decreases along gestation. The fact that the time course of these changes is different from what is observed by cervical length measurements demonstrate that the two measurements contain different information. Accurate biomechanical assessment of the pregnant cervix might therefore become yet another tool in cervical assessment. It seems justified to evaluate these biomechanical tests on a larger scale in different populations, next to morphological cervical assessment as well as the use of biomarkers. We have therefore embarked on a larger clinical study comparing all these modalities.

### WHAT'S ALREADY KNOWN ABOUT THIS TOPIC?

- There is a need to improve existing methods for assessing risk of premature delivery or successful induction of labor.
- Quantitative determination of physical properties of the cervix, such as its stiffness, might provide useful criteria.

### WHAT DOES THIS STUDY ADD?

- Quasi-static elastography cannot quantify cervical stiffness and cannot be reliably used to predict preterm delivery.
- New biomechanical measurement techniques ('aspiration' and 'cervical consistency index') could demonstrate progressive softening of the pregnant cervix and might be used for diagnosis.



10. Vargis E, Brown N, Williams K, *et al.* Detecting biochemical changes in the rodent cervix during pregnancy using Raman spectroscopy. *Ann Biomed Eng* 2012;40:1814–24.
11. Timmons B, Akins M, Mahendroo M. Cervical remodeling during pregnancy and parturition. *Trends Endocrinol Metab* 2010;21:353–61.
12. Breeveld-Dwarkasing V, de Boer-Brouwer M, Koppele J, *et al.* Regional differences in water content, collagen content, and collagen degradation in the cervix of nonpregnant cows. *Biol Reprod* 2003;69:1600–7.
13. Aughey E, Calder A, Coutts J, *et al.* Pregnancy-associated changes in the physical and microscopic characteristics of the ovine cervix. *J Anat* 1993;136:389–99.
14. Myers K, Socrate S, Tzeranis D, House M. Changes in the biochemical constituents and morphologic appearance of the human cervical stroma during pregnancy. *Eur J Obstet Gynecol Reprod Biol* 2009;144:82–9.
15. Winkler M, Rath W. Changes in the cervical extracellular matrix during pregnancy and parturition. *J Perinat Med* 1999;27:45–61.
16. Petersen L, Uldbjerg N. Cervical collagen in non-pregnant women with previous cervical incompetence. *Eur J Obstet Gynecol Reprod Biol* 1996;67:41–5.
17. Buckingham J, Selden R, Danforth D. Connective tissue changes in the cervix during pregnancy and labor. *Ann N Y Acad Sci* 1962;97:733–41.
18. Uldbjerg N, Ekman G, Malmström A, *et al.* Ripening of the human uterine cervix related to changes in collagen, glycosaminoglycans and collagenolytic activity. *Am J of Obstet Gynecol* 1983;147:662–6.
19. Feltovich F, Nam K, Hall T. Quantitative ultrasound assessment of cervical microstructure. *Ultrasound Imaging* 2010;32:131–42.
20. Timmons B, Akins M, Mahendroo M. Cervical remodeling during pregnancy and parturition. *Trends Endocrinol Metab* 2010;21(6): 353–61. doi: 10.1016/j.tem.2010.01.011.
21. Parra-Saavedra M, Gomez L, Barrero A, *et al.* Prediction of preterm birth using the cervical consistency index. *Ultrasound Obstet Gynecol* 2011;38:44–51.
22. Badir S, Mazza E, Bajka M. Cervical softening occurs early in pregnancy: characterization of cervical stiffness in 100 healthy women using the aspiration technique. *Prenat Diagn* 2013. DOI: 10.1002/pd.4116, online
23. Feltovich H, Hall T, Berghella V. Beyond cervical length: emerging technologies for assessing the pregnant cervix. *Am J Obstet Gynecol* 2012;207:1–10.
24. Reusch LM, Anderson JJ, Carlson LC, *et al.* Detecting cervical microstructure via ultrasound and optical microscopy. Proceedings of the 2010 IEEE Ultrasonics Symposium, San Diego, CA, Oct. 11–14, 2011.
25. Vargis E, Webb CN, Paria BC, *et al.* Detecting changes during pregnancy with Raman spectroscopy. Proceedings of the 2011 Biomedical Sciences and Engineering Conference: Image Informatics and Analytics in Biomedicine, Knoxville, TN, March 15–17, 2011.
26. Reusch LM, Nam K, Anderson JJ, Feltovich H, Kliewer MA, Harter JM, Hall TJ. Quantitative ultrasound for evaluating human cervical microstructure, Proceedings of Ultrasonics, IEEE Symposium - IUS, pp. 2252–5, 2009. DOI: 10.1109/ULSYM.2009.5441812.
27. Ophir J, Céspedes I, Ponnekanti H, *et al.* Elastography: a quantitative method for imaging the elasticity of biological tissues. *Ultrasound Imaging* 1991;13(2):111–34.
28. J Bamber, D Cosgrove, CF Dietrich, *et al.* EFSUMB guidelines and recommendations on the clinical use of ultrasound elastography. Part 1: basic principles and technology. *Ultraschall in Med* 2013;34:169–84.
29. Treece G, Lindop J, Chen L, *et al.* Real-time quasi-static ultrasound elastography. *Interface Focus* 2011, 1, doi: 10.1098/rsfs.2011.0011
30. Cosgrove D, Piscaglia F, Bamber J, *et al.* EFSUMB guidelines and recommendations on the clinical use of ultrasound elastography. Part 2: clinical applications, *Ultraschall in Med.*, 2013, online
31. Thomas A Imaging of the cervix using sonoelastography. *Ultrasound Obstet Gynecol* 2006;28:356–7.
32. Yamaguchi S, Kamel Y, Kozuma S, Taketani Y. Tissue elastography imaging of the uterine cervix during pregnancy. *J Med Ultrason* 2007; 34(4):209–10.
33. Swiatkowska-Freund M, Preis K. Elastography of the uterine cervix: implications for success of induction of labor. *Ultrasound Obstet Gynecol* 2011;38:52–6.
34. Molina FS, Gómez LF, Florido J, *et al.* Quantification of cervical elastography: a reproducibility study. *Ultrasound Obstet Gynecol* 2012;39:685–9.
35. Khalil MR, Thorsen P, Uldbjerg N. Cervical ultrasound elastography may hold potential to predict risk of preterm birth. *Dan Med J* 2013;60(1):A4570.
36. Hernandez-Andrade E, Hassan S, Ahn H, *et al.* Evaluation of cervical stiffness during pregnancy using semiquantitative ultrasound elastography. *Ultrasound Obstet Gynecol* 2013;41:152–61.
37. Molina FS, Rus G, Gomez LF, *et al.* Reply. *Ultrasound Obstet Gynecol* 2012;40:612–3.
38. Fruscalzo A, Schmitz R. Reliability of cervix elastography in late first and second trimester of pregnancy. *Ultraschall Med* 2012;33:1–7.
39. Fruscalzo A, Steinhard J, Londero AP, *et al.* Reliability of quantitative elastography of the uterine cervix in at-term pregnancies. *J Perinat Med* 2013. DOI 10.1515/jpm-2012-0180aop
40. Fruscalzo A, Schmitz R. Quantitative cervical elastography in pregnancy. *Ultrasound Obstet Gynecol* 2012;40:612–3.
41. Mazza E, Nava A, Hahnloser D, *et al.* The mechanical response of human liver and its relation to histology: an in vivo study. *Med Image Anal* 2007;11:663–72.
42. Hollenstein M, Mazza E. Mechanical characterization of the human liver. In *Computer Models in Biomechanics: From Nano to Macro*, Holzapfel G, Kuhl E (eds). New York: Springer. 2012. DOI: 10.1007/978-94-007-5464-5\_26.
43. Mazza E, Nava A, Bauer M, *et al.* Mechanical properties of the human uterine cervix: an in vivo study. *Med Image Anal* 2006;10:125–36.
44. Bauer M, Mazza E, Jabareen M, *et al.* Assessment of the in vivo biomechanical properties of the human uterine cervix in pregnancy using the aspiration test. *Eur J Obstet Gynecol Reprod Biol* 2009;144:77–81.
45. Badir S, Bajka M, Mazza E. A novel procedure for the mechanical characterization of the uterine cervix during pregnancy. *J Mech Behav Biomed Mater* 2013;27:143–53.
46. Myers K, Paskaleva A, House M, Socrate S. Mechanical and biochemical properties of human cervical tissue. *Acta Biomater* 2008;4:104–16.
47. McFarlin BL, Bigelow TA, Laybed Y, *et al.* Ultrasonic attenuation estimation of the pregnant cervix: a preliminary report. *Ultrasound Obstet Gynecol* 2010;36:218–25.
48. Kuwata, T, Matsubara, S, Taniguchi, N, *et al.* A novel method for evaluating uterine cervical consistency using vaginal ultrasound gray-level histogram. *J Perinat Med* 2010;38(5):451–567.
49. Tekesin I, Wallwiener D, Schmidt S. The value of quantitative ultrasound tissue characterization of the cervix and rapid fetal fibronectin in predicting preterm delivery. *J Perinat Med* 2005;33(5):383–91.
50. Stein W, Hellmeyer L, Schmidt S, Tekesin I. Intraobserver and interobserver reliability of transvaginal cervical length measurements and quantitative ultrasound tissue characterization of the cervix in the second and third trimester of pregnancy. *Ultraschall Med* 2011;32:169–74.
51. Maul H, Mackay L, Garfield R. Cervical ripening: biochemical, molecular, and clinical considerations. *Clin Obstet & Gynecol* 2006;49:70–6.
52. Schlembach D, MacKay L, Shi L, *et al.* Cervical ripening and insufficiency: from biochemical and molecular studies to in vivo clinical examination. *Eur J Obstet Gynecol Reprod Biol* 2009;144S: S70–6.
53. O'Connell MP, Tidy J, Wisher SJ, *et al.* An in vivo comparative study of the pregnant and nonpregnant cervix using electrical impedance measurements. *BJOG* 2000;107(8):1040.
54. O'Connell MP, Avis NJ, Brown BH, *et al.* Electrical impedance measurements: an objective measure of prelabor cervical change. *J Matern Fetal Neonatal Med* 2003;14(6):389–91.
55. Gandhi S, Walker D, Milnes P, *et al.* Electrical impedance spectroscopy of the cervix in non-pregnant and pregnant women. *Eur J Obstet Gynecol Reprod Biol* 2006;129:145–9.
56. Jokhi RP, Brown BH, Anumba DO. The role of cervical electrical impedance spectroscopy in the prediction of the course and outcome of induced labour. *BMC Pregnancy Childbirth* 2009;9:40. doi: 10.1186/1471-2393-9-40.
57. Hornung R, Spichigt S, Banos A, *et al.* Frequency-domain near-infrared spectroscopy of the uterine cervix during regular pregnancies. *Lasers Med Sci* 2011;26:205–12.
58. Thomas A, Kummel S, Gemeinhardt O, Fischer T. Real-time sonoelastography of the cervix: tissue elasticity of the normal and abnormal cervix. *Acad Radiol* 2007;14:193–200.
59. Feltovich H, Hall T. Quantitative imaging of the cervix: setting the bar. *Ultrasound Obstet Gynecol* 2013;41:121–8.