

## Twin-Twin Transfusion Syndrome during the 2nd Trimester Is Associated with Small Intertwin Hemoglobin Differences

*N.J. Saunders, R.J.M. Snijders, K.H. Nicolaides*

Harris Birthright Research Centre for Fetal Medicine, King's College School of Medicine, London, UK

**Key Words.** Cordocentesis · Twin-twin transfusion syndrome · Polyhydramnios · Fetal blood · Hemoglobin concentration

**Abstract.** In four twin pregnancies presenting with acute 2nd-trimester polyhydramnios due to presumed twin-twin transfusion syndrome, the fetal hemoglobin concentration was measured in samples obtained by cordocentesis. In no instance did the twin pair difference in the hemoglobin concentration exceed 2.7 g/dl.

### Introduction

One of the widely accepted criteria for the diagnosis of twin-twin transfusion syndrome is an intertwin disparity in the hemoglobin concentration of 5 g/dl or more. This value appears to have been derived from the study of small numbers of live-born term infants [1]. The aim of the present study is to examine the validity of this criterion in pregnancies with presumed twin-twin transfusion syndrome presenting with acute polyhydramnios during the 2nd trimester of pregnancy.

### Patients and Methods

Cordocentesis and blood sampling from both fetuses were performed in four twin pregnancies presenting with acute polyhydramnios at 19-23 (mean 21) weeks of gestation. Fetal blood samples (2 ml) were collected into isotonic edetic acid solution for

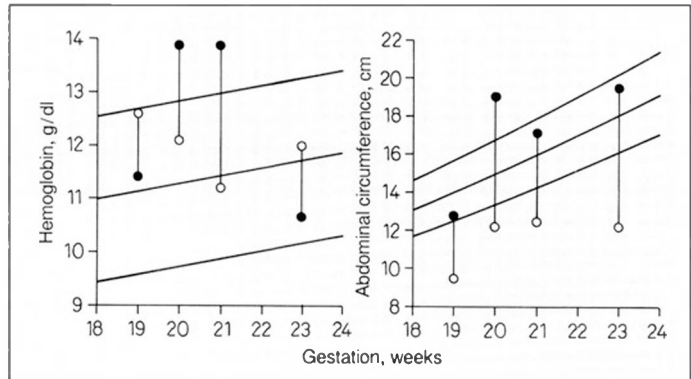
Kleihauer testing, hemoglobin measurement, and extended blood grouping and into heparin for karyotyping.

Detailed ultrasonographic examination revealed no obvious malformation in any of the fetuses, but they were discordant in size and separated by a thin membrane; there was a single placenta. In each case the larger twin was surrounded by polyhydramnios and appeared to have a distended bladder. The smaller twin appeared 'fixed' to the placenta because of oligohydramnios, and no bladder could be demonstrated. Three of the recipient twins demonstrated features of hydrops.

### Results

In all cases Kleihauer testing confirmed that the blood samples contained 100% fetal red cells. Furthermore, in each twin pair monozygosity was suggested by extended blood group and karyotype analysis. The abdominal circumference and the hemoglobin concentration for each twin are shown in fig-

Fig. 1. Abdominal circumference and hemoglobin concentrations in the recipient (○) and donor (●) fetus of four twin pairs, plotted on the reference ranges (mean and 5th and 95th centiles) for singleton pregnancies.



ure 1. Although there were large intertwin differences in the abdominal circumference of between 33 and 59%, the mean hemoglobin difference was only 1.7 g/dl (range 1.2–2.7). In 2 cases the higher hemoglobin value was found in the presumed donor (i.e., the smaller baby with oligohydramnios). In all pregnancies fetal loss occurred within 7 days of the cordocentesis; in 3 cases there was a spontaneous abortion and in the 4th intrauterine death of both twins.

## Discussion

In twin pregnancies presenting with acute 2nd-trimester polyhydramnios due to presumed twin-twin transfusion syndrome, the intertwin hemoglobin difference is much less than the established criterion of 5 g/dl. Furthermore, the recipient does not necessarily have a higher hemoglobin concentration than the donor.

These findings suggest that the underlying pathophysiology of twin-twin transfusion syndrome is likely to be more complex than the simple mechanistic concept of acute shifts in blood volume resulting in anemia

and polycythemia in donor and recipient twins, respectively. Furthermore, although polyuria in the recipient appears to be responsible for the polyhydramnios [2], it would be surprising if the expansion of the intravascular compartment and the resulting increase in urine production were entirely due to transfused blood from the donor. For example, the mean fetoplacental blood volume in a normal singleton pregnancy at 22 weeks of gestation is 45 ml [3] which is far too small to account for the massive volumes of amniotic fluid which continue to be produced under this condition.

An alternative hypothesis is that both the severe early-onset growth retardation in the donor and the development of twin-twin transfusion syndrome are a consequence of uteroplacental insufficiency affecting the donor twin. Increased peripheral resistance in the placental circulation of the donor twin would promote the shunting of blood to the recipient twin through the vascular anastomoses which are invariably present in all monochorionic twin pregnancies [4]. Impaired placental function prevents compensatory shift of fluid from the mother to the donor twin, and, therefore, dilutional ane-

mia does not occur. The recipient twin does not become polycythemic because the increase in colloid osmotic pressure due to the transfusion will draw fluid from the mother, resulting in expansion of the intravascular compartment, polyuria, and polyhydramnios. Thus volume overload and diuresis continue, and a vicious cycle is established.

The very poor outcome in these 4 cases is compatible with other published studies [5–7]. However, given the close temporal relation between cordocentesis and miscarriage, it is possible that the procedure contributed to the fetal losses. Whilst cordocentesis may ultimately prove to have a role in the diagnosis of twin-twin transfusion syndrome, antenatal measurement of hemoglobin concentration would appear to be of little diagnostic value in this condition.

## References

- 1 Rausen AR, Seki M, Strauss L: Twin transfusion syndrome. *J Pediatr* 1965;66:613–628.
- 2 Rosen DJD, Rabinowitz R, Beyth Y, Fejgin MD, Nicolaides KH: Fetal urine production in normal twins and in twins with acute polyhydramnios. *Fetal Diagn Ther* 1990;5:57–60.
- 3 Nicolaides KH, Clewell WH, Rodeck CH: Measurement of human fetoplacental blood volume in erythroblastosis fetalis. *Am J Obstet Gynecol* 1987;157:50–53.
- 4 Robertson EG, Neer KJ: Placental injection studies in twin gestation. *Am J Obstet Gynecol* 1983;147:170–173.
- 5 Gonsoulin W, Moise KJ, Kirshon B, Cotton DB, Wheeler JM, Carpenter RJ: Outcome of twin-twin transfusion diagnosed before 28 weeks of gestation. *Obstet Gynecol* 1990;75:214–216.
- 6 Patten RM, Mack LA, Harvey D, Cyr DR, Pretorius DH: Disparity of amniotic fluid volume and fetal size: Problem of the stuck twin. US studies. *Radiology* 1989;172:153–157.
- 7 Chescheir NC, Seeds JW: Polyhydramnios and oligohydramnios in twin gestations. *Obstet Gynecol* 1988;71:882–884.

Received: August 1, 1991

Accepted: August 30, 1991

K.H. Nicolaides, MD  
 Harris Birthright Research Centre  
 for Fetal Medicine  
 Department of Obstetrics and Gynaecology  
 King's College School of Medicine  
 Denmark Hill  
 London SE5 8RX (UK)