

On discharge from the hospital the patient was placed on methyldopa 500 mg orally every six hours. Predischarge blood pressures stabilized to a systolic level of 130 to 150 mm Hg and a diastolic level of 80 to 100 mm Hg.

Comment

Bromocriptine mesylate (2-bromo- α -ergocryptine methanesulfonate) (Parlodel, Sandoz, East Hanover, N.J.), an ergot alkaloid derivative, prevents the release of prolactin from the anterior pituitary gland by virtue of its dopamine agonist properties acting on the dopamine receptors on the prolactin-secreting cells to suppress their secretion of prolactin. Relatively common side effects of bromocriptine include nausea, vomiting, faintness, and dizziness. Although studies have shown a hypotensive effect that sometimes occurs just after initiation of therapy, sporadic reports have emerged that describe hypertension, seizures, stroke, and acute myocardial infarction in the postpartum period thought to be related to bromocriptine, usually with several days' delay between initiation of treatment and development of complications.^{1,2}

Of interest is the possible role played by the cocaine use in this patient. The drug screen was positive on initial examination but negative for cocaine during the second admission at the time of complications. Acute use of cocaine is associated with hypertensive and cardiac effects. It has been suggested that chronic cocaine use, by the depletion of brain dopamine reserves, cre-

ates a condition of supersensitivity of dopamine receptors that is believed to be central in cocaine-craving behavior. Bromocriptine has been recently used to combat this craving behavior by reversing the supersensitivity. It may be that the flux in dopamine agonism and in dopamine receptor sensitivity caused by temporally related cocaine and bromocriptine use resulted in vasospasm in this patient.²

Even without recent or concomitant cocaine use, it may be possible that a subpopulation of patients exists wherein bromocriptine exerts vasospastic effects similar to other ergot alkaloids. An example may be the description of Raynaud's phenomenon in some patients with acromegaly or infertility who receive bromocriptine therapy.

Until more data are available the authors recommend avoidance of postpartum bromocriptine administration where there is a history of recent cocaine use. In addition, postpartum women for whom bromocriptine is prescribed deserve close monitoring for development of adverse cerebrovascular or cardiovascular effects and prompt evaluation of any symptoms.

REFERENCES

1. Postpartum hypertension, seizures, strokes reported with bromocriptine. FDA Drug Bull 1984;14:P3-4.
2. Miller LG, Bakht F, Baker T, Kirshon B. Possible cocaine predisposition to adverse cerebrovascular and cardiovascular sequelae of bromocriptine administered postpartum. J Clin Pharmacol 1989;29:781-5.

Doppler examination of the middle cerebral artery in anemic fetuses

Sanjay Vyas, MD, Kypros H. Nicolaides, MD, and Stuart Campbell, MD

London, England

In 24 red cell isoimmunized pregnancies the fetal middle cerebral artery mean blood velocity increased with anemia. The blood velocity was not related to fetal blood PO_2 and the relation of increased velocity to anemia was not affected by the pulsatility index. These findings suggest that the hyperdynamic circulation is a consequence of decreased blood viscosity. (AM J OBSTET GYNECOL 1990;162:1066-8.)

Key words: Doppler ultrasonography, red cell isoimmunization, cordocentesis, fetal circulation, fetal anemia

From the Harris Birthright Research Centre for Fetal Medicine, Department of Obstetrics and Gynaecology, King's College School of Medicine.

Received for publication October 3, 1989; accepted October 11, 1989.

Reprint requests: Kypros H. Nicolaides, MD, Harris Birthright Research Centre for Fetal Medicine, Department of Obstetrics and Gynaecology, King's College School of Medicine, Denmark Hill, London SE5 8RX, England.

6/11/7366

Fetal anemia is associated with a hyperdynamic circulation.¹ This may be a result of first, chemoreceptor-mediated increased cardiac contractility or peripheral vasodilatation, and second, increased cardiac output because of increased venous return, the consequence of decreased blood viscosity, because the major determinant of the latter is hematocrit. This study investi-

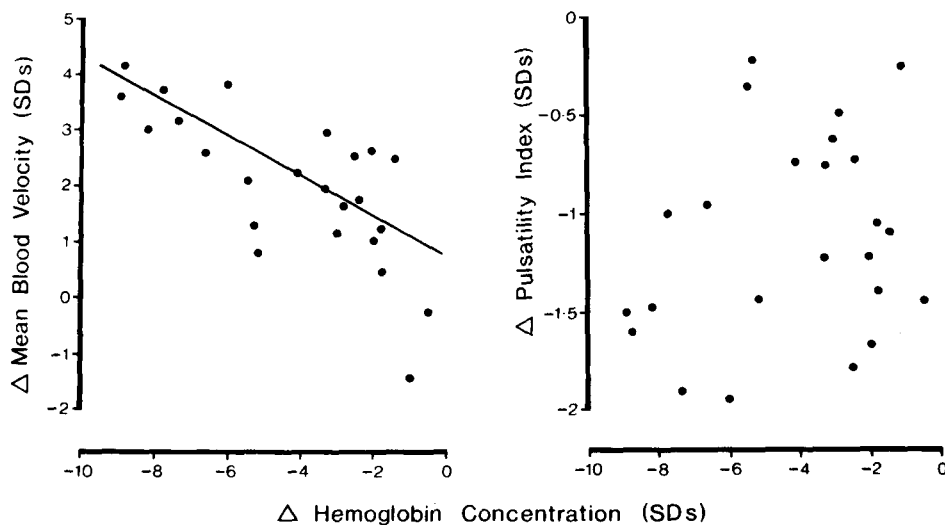


Fig. 1. Relationship of differences in fetal hemoglobin concentration, middle cerebral artery mean blood velocity, and pulsatility index.

gates these possibilities by examining the effect of anemic hypoxia on blood velocity and impedance to flow in the middle cerebral artery.

Patients and methods

Doppler ultrasonographic studies were performed in 24 previously untransfused, nonhydropic fetuses from red cell isoimmunized pregnancies at 18 to 35 weeks' gestation. The middle cerebral artery intensity-weighted time-averaged mean blood velocity and pulsatility index were measured by spectral analysis of flow velocity waveforms obtained by pulsed Doppler ultrasonography after vessel identification by color flow imaging (Acuson 128, Mountain View, Calif.). During the Doppler studies care was taken to minimize fetal head compression, because this alters the flow velocity waveforms.² Subsequently, cordocentesis was performed for measurement of hemoglobin concentration. In 22 of the cases PO_2 and pH were also measured and the oxygen content was calculated. The observed blood and Doppler values in each fetus were expressed as the number of SDs by which they differed from the appropriate mean for gestation of our reference ranges (difference in hemoglobin, PO_2 , oxygen content, mean blood velocity and pulsatility index, respectively).

Results

The difference in mean blood velocity was significantly associated with the difference in hemoglobin (Fig. 1; $n = 24$, $r = -0.723$, $p < 0.0001$, constant = 0.460, slope = -0.367 , residual SD = 0.948) and the difference in oxygen content ($n = 22$; $r = -0.733$, $p < 0.001$, constant = 0.313, slope = -0.473 , residual SD = 0.945), but not the difference in PO_2 ($n = 22$, $r = 0.160$) or pH ($n = 22$, $r = -0.146$). The mean dif-

ference in pulsatility index was significantly lower than the normal mean for gestation (mean difference = -1.117 SDs, SE = 0.106, $t = -10.58$, $p < 0.0001$). However, there were no significant associations with the difference in hemoglobin ($n = 24$, $r = 0.257$), PO_2 ($n = 22$, $r = 0.415$), pH ($n = 22$, $r = 0.241$), or oxygen content ($n = 22$, $r = 0.408$).

Multiple regression analysis showed that gestational age and the difference in mean blood velocity explained 62.2% of the variation in the difference in hemoglobin:

$$(\text{dHb} = -5.724) + (0.153 \times \text{gestational age}) - (1.233 \times \text{dVm}; \text{residual SD} = 1.714 \text{ SDs})$$

where d is the number of SDs of difference from the mean, Hb is hemoglobin, and Vm is mean blood velocity. Although the difference in mean blood velocity was significantly associated with the difference in pulsatility index ($n = 24$, $r = -0.418$, $p < 0.05$), the addition of the difference in pulsatility index did not significantly improve this model.

Comment

In fetal anemia, middle cerebral artery mean blood velocity is increased and pulsatility index is decreased. Because these hemodynamic changes are not significantly associated with the difference in PO_2 , they are unlikely to be a result of peripheral chemoreceptor-mediated increased cardiac contractility or cerebral vasodilatation, respectively.

Although the relationship between the differences in pulsatility index and oxygen content did not reach statistical significance, it is possible that the low oxygen content of anemia causes tissue hypoxia and consequent local vasodilatation. Alternatively, the low pul-

satility index may be a result of reduced blood viscosity. However, the data of this study indicate that decreased impedance to flow, irrespective of the underlying cause, is not significantly related to the degree of fetal anemia.

The hyperdynamic circulation of anemic fetuses, manifested in high mean blood velocity in both the middle cerebral artery and aorta, is unlikely to be a result of a purposeful compensatory mechanism, but rather the beneficial consequence of decreased blood viscosity and increased venous return.

REFERENCES

1. Nicolaides KH, Bilardo CM, Campbell S. Prediction of fetal anemia by measurement of the mean blood velocity in the fetal aorta. *AM J OBSTET GYNECOL* 1990;162:209-12.
2. Vyas S, Nicolaides KH, Bower S, Campbell S. Middle cerebral artery flow velocity waveforms in fetal hypoxaemia. *Br J Obstet Gynaecol* 1990 [In press].

Prenatal diagnosis of valvar aortic stenosis by Doppler echocardiography and magnetic resonance imaging

Toshiyuki Hata, MD,^a Ken Makihara, MD,^a Showa Aoki, MD,^a Masuo Kusakari, MD,^a
Kohkichi Hata, MD,^a Kenji Kishida, MD,^b and Manabu Kitao, MD^a

Izumo, Japan

We present herein a case of valvar aortic stenosis diagnosed antenatally, using color and pulsed Doppler echocardiography and magnetic resonance imaging. The benefit and advantages of the use of magnetic resonance imaging, complementary to the Doppler echocardiography, are discussed. (*AM J OBSTET GYNECOL* 1990;162:1068-70.)

Key words: Prenatal diagnosis, aortic stenosis, Doppler echocardiography, magnetic resonance imaging

Valvar aortic stenosis occurs in approximately 3% to 6% of patients with congenital cardiovascular defects. An isolated valvar aortic stenosis seldom causes symptoms in infancy, but occasionally the lesion can be related to severe and intractable heart failure. There are only two reports of a prenatal diagnosis of aortic stenosis made by fetal Doppler echocardiography done at 35 and 32 weeks of gestation, respectively.^{1,2} In the first report, in utero maximum systolic velocity of the ascending aorta was 1.7 m/sec with pulsed Doppler ultrasonography.¹ In the second report, color Doppler ultrasonography depicted a turbulent blood flow pattern across the aortic valve, but the maximum systolic velocity across the aortic valve could not be measured.² In both cases postnatal maximum systolic velocities across the aortic valve were 3.6 and 1.6 m/sec, respectively. There were significant discrepancies between

prenatal and postnatal maximum systolic velocities across the aortic valve. We report here a case of valvar aortic stenosis diagnosed in utero at 28 weeks of gestation. There was clear evidence of a high turbulent systolic blood flow velocity (4 m/sec) and poststenotic dilatation of the aorta by color and pulsed Doppler ultrasonography. Magnetic resonance imaging depicted poststenotic dilatation of the aorta in utero.

Case report

A 27-year-old Japanese woman, gravida 1, para 0, was referred to our ultrasonography clinic at 28 weeks' gestation, for detailed examinations of the fetus. Rheumatoid fever at age 17 years and myocardial infarction at age 24 years were included in her medical history. She had been taking nitroglycerin orally for anginal-like attacks once a week throughout the pregnancy. Fetal echocardiography showed a thickened and abnormal aortic valve and poststenotic dilatation of the ascending aorta. Diameters of aortic valve orifice and widest point of dilated ascending aorta and descending aorta were 4, 10, and 4 mm, respectively. There were no other evident abnormalities of the heart nor was there cardiac enlargement. Doppler color flow mapping revealed a turbulent blood flow pattern (mosaic

From the Departments of Obstetrics and Gynecology^a and Pediatrics,^b Shimane Medical University.

Received for publication August 28, 1989; revised October 2, 1989; accepted October 20, 1989.

Reprint requests: Toshiyuki Hata, MD, Department of Obstetrics and Gynecology, Shimane Medical University, Izumo 693, Japan.
6/11/17615