





# Prenatal cerebellar growth is altered in congenital diaphragmatic hernia on ultrasound

Lennart Van der Veeken<sup>1,2</sup>  | Francesca M. Russo<sup>1,2</sup>  | Ewelina Litwinska<sup>3</sup> | Olga Gomez<sup>4,5,6</sup> | Doaa Emam<sup>1,7</sup> | Liesbeth Lewi<sup>1,2</sup>  | David Basurto<sup>1</sup> | Stephan Van der Veeken<sup>8</sup> | Luc De Catte<sup>1,2</sup> | Eduard Gratacos<sup>4,5,6</sup> | Elisenda Eixarch<sup>4,5,6</sup> | Kypros Nicolaides<sup>3</sup> | Jan Deprest<sup>1,2,9</sup> 

<sup>1</sup>Department of Development and Regeneration, Cluster Woman and Child, Group Biomedical Sciences, KU Leuven University of Leuven, Leuven, Belgium

<sup>2</sup>Clinical Department Obstetrics and Gynaecology, University Hospitals Leuven, Leuven, Belgium

<sup>3</sup>Harris Birthright Research Center for Fetal Medicine, King's College Hospital, London, UK

<sup>4</sup>Fetal i+D Fetal Medicine Research Center, BCNatal - Barcelona Center for Maternal-Fetal and Neonatal Medicine (Hospital Clinic and Hospital Sant Joan de Deu), Institut Clínic de Ginecologia, Obstetrícia i Neonatologia, Barcelona, Spain

<sup>5</sup>Institut d'Investigacions Biomèdiques August Pi i Sunyer, Universitat de Barcelona, Barcelona, Spain

<sup>6</sup>Centre for Biomedical Research on Rare Diseases (CIBER-ER), Barcelona, Spain

<sup>7</sup>Department Obstetrics and Gynaecology, University Hospitals Tanta, Tanta, Egypt

<sup>8</sup>Department of Engineering Management, University of Antwerp, Antwerp, Belgium

<sup>9</sup>Institute for Women's Health, University College London, London, UK

## Correspondence

Jan Deprest, FRCOG, Herestraat 49, 3000 Leuven, Belgium.  
Email: [jan.deprest@uzleuven.be](mailto:jan.deprest@uzleuven.be)

## Funding information

Erasmus + Program of the European Union, Grant/Award Number: 2013-0040; KU Leuven, Grant/Award Number: PDM 05/2018; Fonds Wetenschappelijk Onderzoek, Grant/Award Number: 1804718N; Wellcome Trust, Grant/Award Number: WT101957; Engineering and Physical Sciences Research Council, Grant/Award Number: NS/A000027/1; Great Ormond Street Hospital Charity; "La Caixa" Foundation, Grant/Award Number: LCF/PR/GN14/10270005; Agència de Gestió d'Ajuts Universitaris i de Recerca, Grant/Award Number: 1531; Instituto de Salud Carlos III, Grant/Award Number: PI16/00861; The Cerebra Foundation for the Brain-Injured Child

## Abstract

**Objective:** Children with congenital diaphragmatic hernia (CDH) are at risk for neurodevelopmental delay. Herein we report on prenatal changes in biometry and brain perfusion in fetuses with isolated CDH.

**Study Design:** This retrospective study evaluated fetuses with isolated, left-sided CDH in three European referral centers. Abdominal circumference (AC), femur length (FL), head circumference (HC), transcerebellar diameter (TCD), middle cerebral artery (MCA) Doppler, and ventricular width (VW) were assessed during four gestational periods (<24 weeks, 25–28 weeks, 29–32 weeks, >33 weeks). Z-scores were calculated, and growth curves were created based on longitudinal data.

**Results:** In 367 fetuses, HC, AC and FL were within normal ranges throughout gestation. The TCD diminished with advancing gestational age to fall below the fifth percentile after 32 weeks. A less pronounced but similar trend was seen in VW. The peak systolic velocity of the MCA was consistently approximately 10% lower than normal. Disease severity was correlated to TCD ( $p = 0.002$ ) and MCA doppler values ( $p = 0.002$ ). There were no differences between fetuses treated with FETO and those managed expectantly.

This data has partially been presented orally at the 19th FMF World Congress, Alicante, Spain, June 2019 and as poster presentation at the SMFM 40th Annual Pregnancy Meeting, Dallas, USA, February 2020.

**Conclusion:** Fetuses with isolated left-sided CDH have a small cerebellum and reduced MCA peak systolic velocity. Follow up studies are necessary to determine the impact of these changes on neurodevelopment.

### Key points

#### What's already known about this topic?

- Children with congenital diaphragmatic hernia (CDH) are at increased risk for neurodevelopmental problems. It remains uncertain if brain development is already impaired prenatally

#### What does this study add?

- Fetuses with isolated CDH have a smaller than average cerebellum but normal sized head, which may indicate an altered prenatal brain development in CDH
- This study is the first to report on biometry and cerebellar and ventricular growth curves and brain blood flow in fetuses with CDH

## 1 | INTRODUCTION

Congenital diaphragmatic hernia (CDH) is found in 3–4/10,000 pregnancies and in about 80% of cases it is left-sided.<sup>1</sup> The intrathoracic presence of abdominal viscera interferes with lung development, eventually leading to pulmonary hypoplasia. Postnatally there are variable degrees of ventilatory insufficiency and pulmonary hypertension, which is fatal in up to 30% of neonates. Survivors often suffer from short- and long-term complications,<sup>2,3</sup> including respiratory and gastro-intestinal sequelae. There is also evidence of an increased risk of neurologic disabilities; reported problems include neurodevelopmental delay, low intelligence, autism, as well as learning and behavioral problems.<sup>4</sup> These adverse sequelae have been attributed to certain postnatal events, such as the use of ECMO, general anesthesia for, and the surgical repair itself, perioperative hypoxic brain injury, and a long stay in the neonatal intensive care unit.<sup>5–8</sup>

In congenital heart defects, such as hypoplastic left heart syndrome or severe aortic stenosis, a link between decreased cardiac output and cerebral perfusion on the one hand, and impaired prenatal brain development and neurobehavioral problems later in life, on the other hand, has been described.<sup>9–11</sup> The same mechanism may play a role in CDH; in this defect smaller left ventricular dimensions, and reduced left cardiac output have been reported.<sup>12–15</sup> The functional impact of these remains uncertain, yet we earlier observed a reduced cerebral perfusion, which was proportional to the degree of pulmonary hypoplasia.<sup>15</sup> Prenatal disease severity indicators, such as lung volume and liver position, have already earlier been linked to impaired neurodevelopment.<sup>7,8</sup>

It remains unclear whether brain development is altered as a consequence of postnatal events or complications, or whether brain development is already impaired prenatally. The objective of this study is to report on changes in head biometry and brain perfusion in a consecutive cohort of fetuses with isolated CDH.

## 2 | METHODS

This retrospective study included all consecutive fetuses assessed for isolated left-sided CDH at three European referral centers (University Hospitals Leuven, Belgium; King's College London, United Kingdom, and BCNatal Barcelona, Spain) between January 2007 and May 2019. Exclusion criteria were right-sided or bilateral CDH, presence of associated structural or genetic abnormalities detected pre- or postnatally, and twin pregnancies. Data were collected from measurements performed during four different gestational age periods: 20–23, 24–28, 29–32 and 33–40 weeks, based on first- or second-trimester ultrasound of fetal crown-rump length and head circumference (HC), respectively.

Ultrasound examinations were performed using a 4–8-MHz linear array three-dimensional probe (Voluson 730 Expert or E8/10 machine systems, General Electric, Healthcare, Zipf, Austria). Assessments were done by experienced operators, familiar with prenatal assessment of CDH fetuses. The abdominal circumference (AC) was measured on a transverse circular plane of the fetal abdomen, at the level of the stomach and the bifurcation of the main portal vein. Femur length (FL) was measured from the greater trochanter to the lateral condyle on a plane showing the entire femoral diaphysis and an angle of <45° to the horizontal. The biparietal diameter (BPD) and HC were measured on a standard biparietal view, typically showing two equal hemispheres, the cavum septi pellucidi at one-third of the way from the front to the back, and the posterior horns of the lateral ventricles.<sup>16</sup> Ventricular width was measured at the level of the atrium slightly above the level of the thalami in an axial plane of the fetal brain.<sup>17</sup> Doppler interrogation of blood flow in the middle cerebral artery (MCA) was performed on an axial section of the brain, including the thalami and the cavum septi pellucidi. After identification of the MCA by color Doppler, the pulsed Doppler sample volume was adjusted over the MCA just distal to its emergence from the circle of Willis, keeping the insonation angle as close as possible to

0°. <sup>18</sup> Measurements were done in the absence of maternal and fetal breathing movements. At least three stable waveforms were recorded, traced and averaged to calculate the MCA peak systolic velocity (PSV) and the pulsatility index (PI).

Biometry and brain measurements were corrected for gestational age by transformation to Z-scores based on reference curves from a comparable population. <sup>19–21</sup> Doppler findings were normalized for gestational age by transforming measurements to multiples of the median based on previously published reference values. <sup>22</sup> Severity indicators were retrieved from the medical records and included observed-to-expected lung-to-head ratio (O/E LHR) and liver herniation assessed at 26–27 weeks of gestation or as close as possible to that time point.

Data were analyzed with Prism for Windows version 7.0 (Graphpad Software) and Microsoft Excel (2010). Because of the large sample size, data were considered as normally distributed and therefore expressed as mean  $\pm$  SD. Z-scores from biometric and Doppler findings in CDH cases were compared to normative data using the one-sampled *t*-tests. Two-sampled *t*-test was used to compare findings in fetuses treated with Fetoscopic Endoluminal Tracheal Occlusion (FETO) and those managed expected. Correlations were assessed using Pearson's correlation coefficient or using *F*-test. For individual growth curves, we used the data from fetuses with measurements in at least three different time periods and interpolated an individual cubic curve. After that, the average curve was calculated from the averages of these curves. This curve was compared to the normal growth curve using the extra sum-of-squares *F* test.

## 3 | RESULTS

### 3.1 | Study population

We identified 367 fetuses with isolated left-sided CDH. Pulmonary hypoplasia was predicted to be severe in 145 cases (40%), moderate in 125 (34%), and mild in 97 (26%). Of all fetuses, 204 (56%) had liver herniation. In 163 fetuses FETO was performed. Longitudinal data were available for 176 patients, of whom 88 had FETO.

### 3.2 | Biometry

In the CDH fetuses, FL and AC measurements were slightly lower than average but remained within the respective normal range throughout gestation (the average Z-score for FL was  $-0.45 \pm 1.1$  and for AC it was  $-0.52 \pm 0.95$ ) (Table 1, Figure 1). The BPD and HC Z-scores were within normal ranges throughout gestational age (Table 1); in the earliest gestational age group (<24 weeks), the mean HC was 1% larger than normal (Z-score:  $0.07 \pm 0.47$ ) and the most advanced gestational age group ( $\geq 33$  weeks) the mean HC was 4% larger than normal (Z-score:  $0.46 \pm 0.54$ ). For the BPD, there was a less pronounced but similar pattern. A similar trend was visible for the average growth curve based on longitudinal data ( $R^2 = 0.92$  for

BPD and HC), which remained within normal limits, though displaying a trend to increase when compared to normal fetuses (Figure 1).

### 3.3 | Cerebellum and lateral ventricle

In the CDH fetuses, the TCD Z-score decreased during gestation, from 2% smaller than average at <24 weeks (Z-score:  $-0.49 \pm 1.34$ ) to 7% smaller in at  $\geq 33$  weeks (Z-score:  $-1.85 \pm 1.70$ ); in the latter group, 42% of fetuses had TCD values below the fifth percentile. This is reflected in the average growth curve ( $R^2 = 0.80$ ), which bends downwards from 28 weeks onwards, and falls below the fifth percentile at  $\geq 33$  weeks (Figure 2). In addition, average ventricle width decreased during gestation from 9% smaller than average at <24 weeks (Z-score:  $-0.45 \pm 1.00$ ) to 23% smaller at  $\geq 33$  weeks (Z-score:  $-0.97 \pm 1.12$ ) (Table 1, Figure 2).

### 3.4 | MCA Doppler

In the CDH fetuses, the MCA PI was lower than normal until 28 weeks of gestation and increased thereafter towards the mean of the normal range (Table 1, Figure 3). Conversely, the MCA PSV, was on average 10% (range: 8%–12%) lower than in normal fetuses, irrespective of gestational age (Table 1, Figure 3).

### 3.5 | Correlations

There was no correlation between the disease severity markers O/E LHR and liver position and BPD, HC or TCD. A post-hoc analysis demonstrated that the TCD was weakly, positively correlated to the O/E LHR after 28 weeks ( $r = 0.19$ ;  $p = 0.002$ ) but not before (Figure 4). The O/E LHR was weakly, but significantly, correlated to AC and FL measurements ( $r = 0.2$ ;  $p < 0.0001$  for both). Furthermore, fetuses with liver herniation had a significantly lower MCA PSV compared to those without, and this was so throughout gestation ( $p = 0.0001$ ) (Figure 4). The findings on fetal biometry and Doppler were not influenced by whether FETO was carried out or not (Table 2).

## 4 | DISCUSSION

The main findings of the study in isolated left-sided CDH the fetal TCD, HC, AC and FL are within the normal range throughout gestation. However, the TCD diminishes with advancing gestation to fall below the fifth percentile after 32 weeks. A less pronounced but similar trend is seen in the lateral cerebral ventricle width. In the MCA Doppler studies, the PSV values were consistently lower than expected, even more so in fetuses with intrathoracic herniation of the liver, while the PI was only lower than normal until 28 weeks. There was no correlation between lung size and head biometry, but

TABLE 1 Z-scores of CDH fetuses of cross-sectional data in gestational age periods

Measurement	Gestational age (weeks)			
	20–23	24–28	29–32	≥33
Abdominal circumference	$-0.60 \pm 1.58^{***}$ (7%)	$-0.65 \pm 0.94^{***}$ (5%)	$-0.46 \pm 0.93^{***}$ (4%)	$-0.28 \pm 0.99^{**}$ (3%)
Femur length	$-0.51 \pm 0.96^{***}$ (5%)	$-0.48 \pm 0.95^{***}$ (4%)	$-0.40 \pm 1.10^{***}$ (7%)	$-0.41 \pm 1.29^{***}$ (5%)
Biparietal diameter	$-0.14 \pm 0.56^{**}$ (1%)	$0.16 \pm 0.50^{***}$ (0%)	$0.13 \pm 0.58^*$ (0%)	$0.20 \pm 0.66^{***}$ (0%)
Head circumference	$0.07 \pm 0.47^*$ (1%)	$0.31 \pm 0.47^{***}$ (3%)	$0.40 \pm 0.48^{***}$ (3%)	$0.46 \pm 0.54^{***}$ (6%)
Transcerebellar diameter	$-0.49 \pm 1.34^{***}$ (12%)	$-0.47 \pm 1.13^{***}$ (11%)	$-1.39 \pm 1.44^{***}$ (28%)	$-1.85 \pm 1.70^{***}$ (42%)
Lateral cerebral ventricle	$-0.45 \pm 1.00^{***}$ (6%)	$-0.56 \pm 1.35^{***}$ (10%)	$-0.72 \pm 1.23^{***}$ (15%)	$-0.97 \pm 1.20^{***}$ (20%)
Middle cerebral artery PI	$-0.70 \pm 0.82^{***}$ (6%)	$-0.34 \pm 0.79^{***}$ (1%)	$0.09 \pm 0.87$ (3%)	$0.40 \pm 1.12^{***}$ (8%)
Middle cerebral artery PSV	$-0.25 \pm 0.60^*$ (0%)	$-0.46 \pm 0.56^{***}$ (0%)	$-0.45 \pm 0.58^{***}$ (0%)	$-0.20 \pm 0.56^{***}$ (0%)

Note: Data are given as mean  $\pm$  SD. Within the brackets are the % of abnormal Z-scores (<2 and 2 Z-scores).

Abbreviation: CDH, congenital diaphragmatic hernia; PI, pulsatility index; PSV, peak systolic velocity.

\* $p < 0.05$ , \*\* $p < 0.001$ , \*\*\* $p < 0.0001$  in one sampled  $t$ -test.

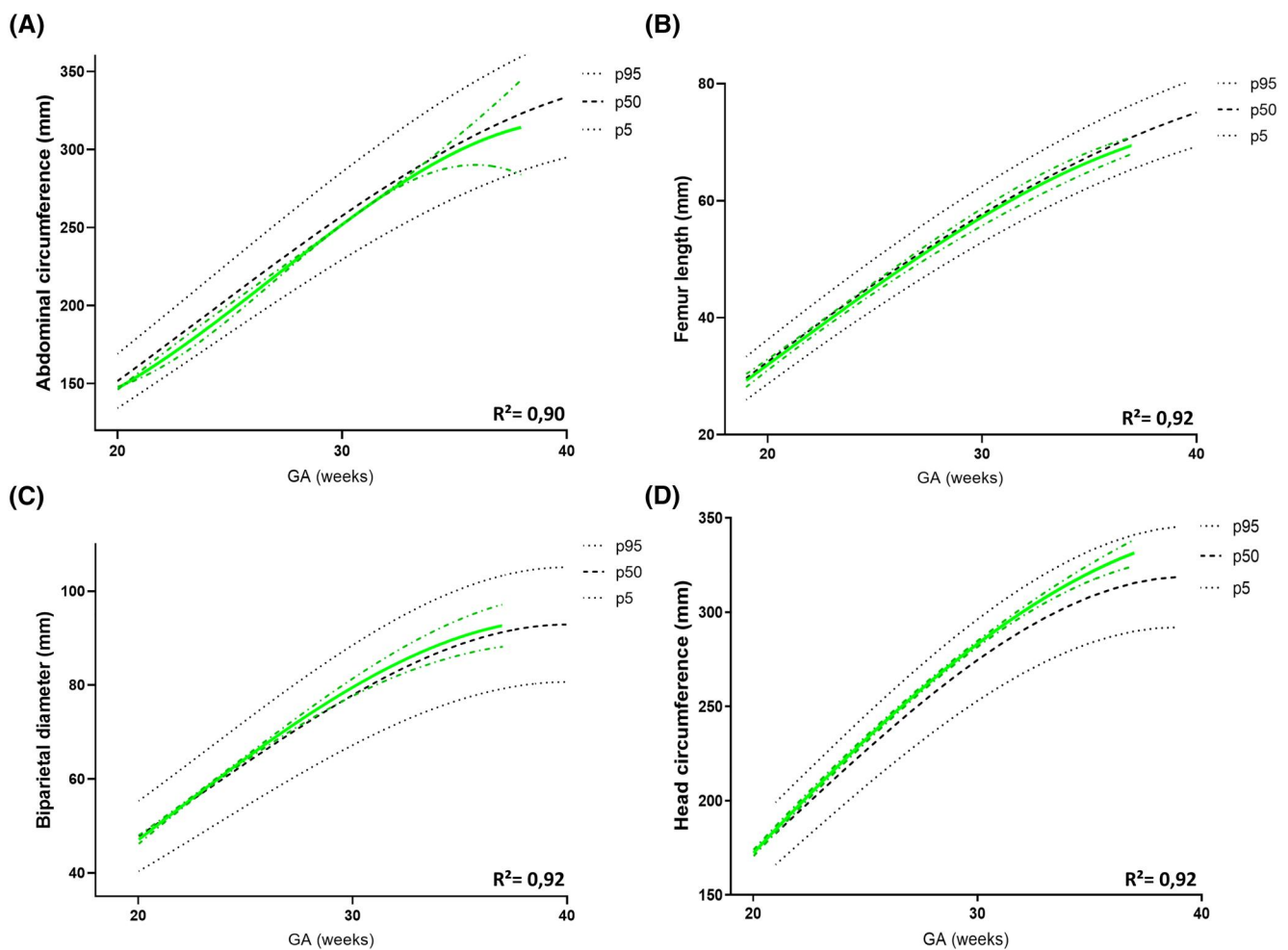
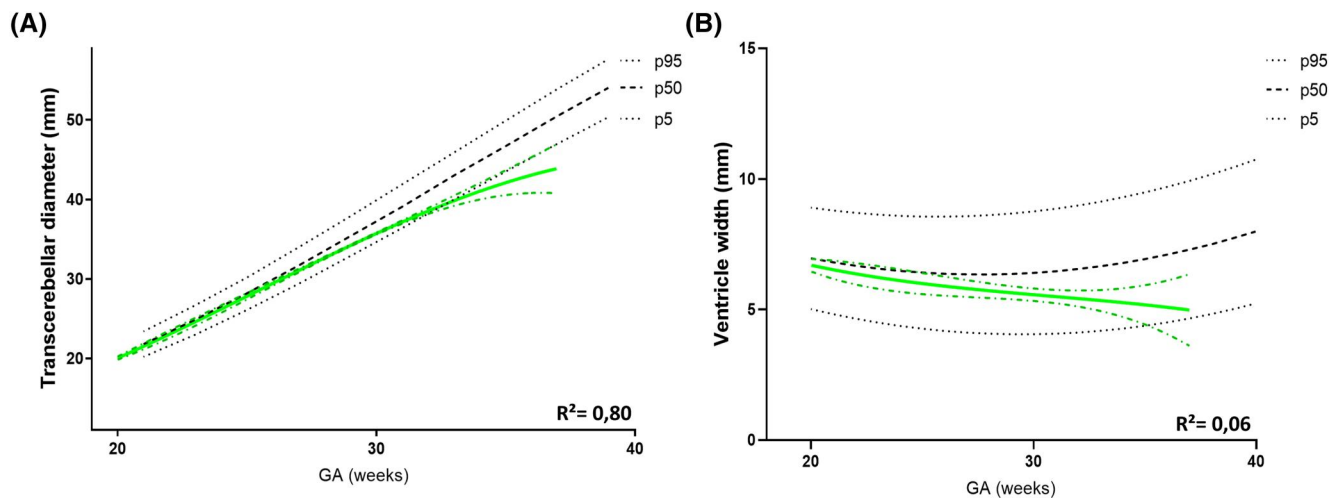
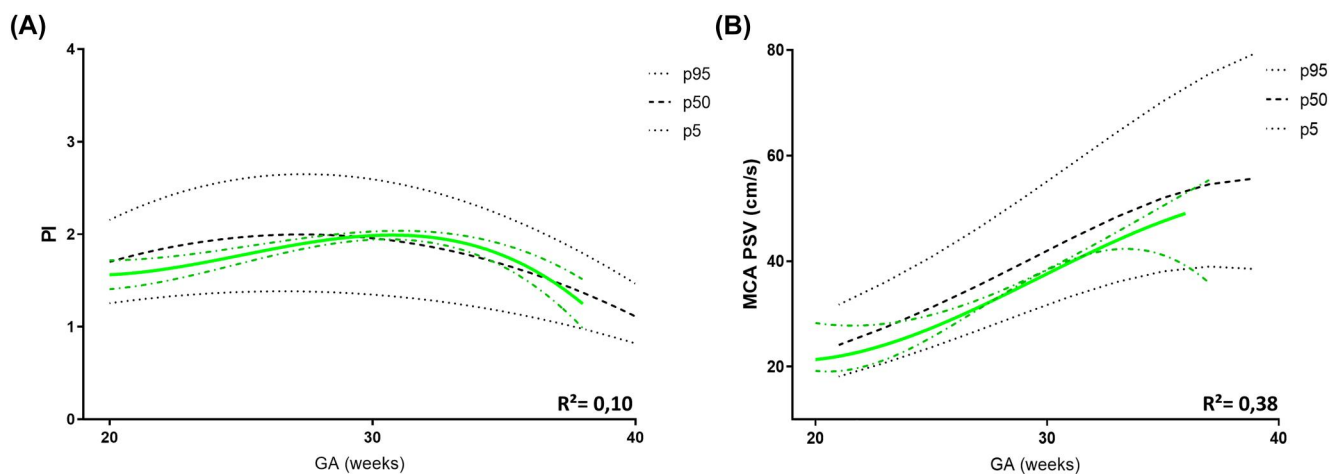


FIGURE 1 Average growth curve of our CDH population (—) with 95% confidence interval (---) compared to reference curves (p5, p50, p95) of a normal population.<sup>19</sup> (A) Abdominal circumference ( $n = 156$ ); (B) Femur length ( $n = 157$ ); (C) Biparietal diameter ( $n = 170$ ); (D) Head circumference ( $n = 175$ ). CDH, congenital diaphragmatic hernia; GA, gestational age [Colour figure can be viewed at [wileyonlinelibrary.com](http://wileyonlinelibrary.com)]



**FIGURE 2** Average growth curve of our CDH population (—) with 95% confidence interval (—) compared to reference curves (p5, p50, p95) of a normal population.<sup>20,21</sup> (A) Transcerebellar diameter ( $n = 106$ ); (B) Ventricle width ( $n = 100$ ). CDH, congenital diaphragmatic hernia; GA, gestational age [Colour figure can be viewed at [wileyonlinelibrary.com](http://wileyonlinelibrary.com)]



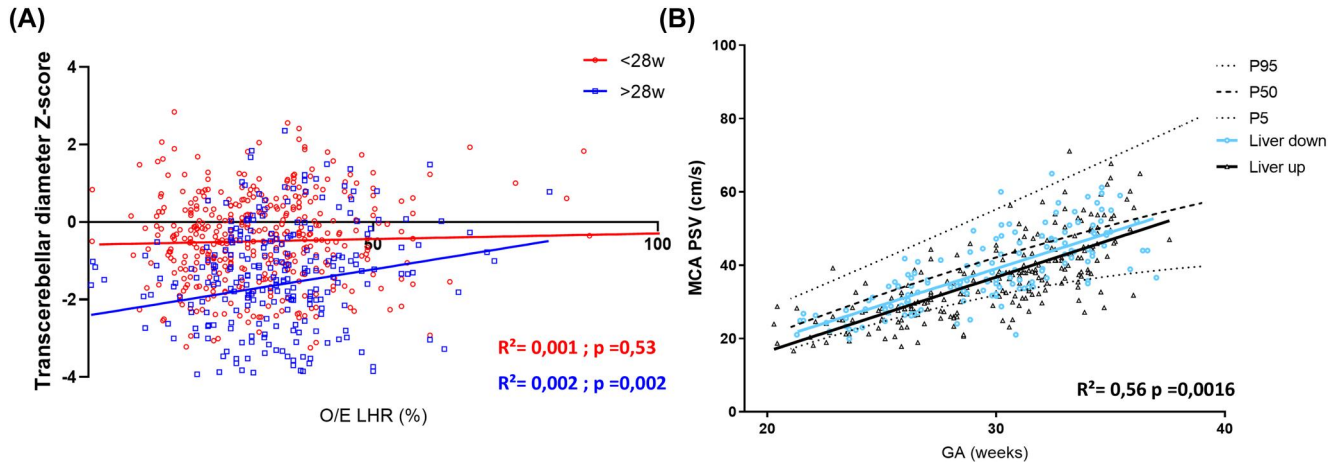
**FIGURE 3** Average longitudinal evolution curve of the MCA of our CDH population (—) with 95% confidence interval compared (—) to reference curves (p5, p50, p95) of a normal population. (A) PI ( $n = 123$ ); (B) PSV ( $n = 121$ ). CDH, congenital diaphragmatic hernia; GA, gestational age; MCA, middle cerebral artery; PI, pulsatility index; PSV, peak systolic velocity [Colour figure can be viewed at [wileyonlinelibrary.com](http://wileyonlinelibrary.com)]

there was a correlation with FL and AC and a correlation with TCD in the third trimester.

In this study, we hypothesized that in fetal CDH decreased cardiac output might lead to decreased brain perfusion and consequent impairment of brain growth. Our observation that the MCA PI are close to or within the normal range during the third trimester, and a consistently lower PSV, might be signs of a decrease in total blood flow through that vessel—although this cannot be proven but it is consistent with that of a previous smaller study.<sup>23</sup> Our finding demonstrate that in fetuses with intrathoracic liver herniation MCA PSV is lower than in those without such herniation and this may be due to the previously reported smaller hearts in fetuses with intrathoracic liver.<sup>24</sup> Another explanation for our finding is that the intrathoracic presence of the liver alters the cardiac angle so that the umbilical blood flow preferentially directed towards the right side of the heart,

instead of the left atrium leading to reduction in MCA perfusion.<sup>25</sup> Our finding that the MCA PI at <28 weeks' gestation is reduced is consistent with the findings of a previous study that reported reduced PI at 22–25 weeks.<sup>14</sup> Reduced MCA PI is considered a compensatory mechanism to redistribute blood flow towards the brain. Our finding of the return of the MCA PI to the normal range, and above, in the third trimester, parallels the observations on simultaneous changes in brain biometry but awaits further explanation.

Another novel finding in our study is that in CDH there is reduction in cerebellar diameter with advancing gestation. Recently, Radhakrishnan et al. reported CDH fetuses to have a shorter anteroposterior vermian length, which in their experience was proportional to the lung volume.<sup>26</sup> Smaller cerebellar volumes have also been described in association with other malformations, such as univentricular heart disease and obstructive left-sided heart defects;



**FIGURE 4** A) Correlation and regression between O/E LHR and TCD in the CDH population before and after 28 weeks GA (<28 weeks ; >28 weeks ). (B) Correlation and regression between MCA PSV and liver herniation in fetuses with left-sided (liver down ; liver up ) congenital diaphragmatic hernia. CDH, congenital diaphragmatic hernia; GA, gestational age; MCA PSV, middle cerebral artery peak systolic velocity; O/E LHR, observed-to-expected lung-to-head ratio; TCD, transcerebellar diameter [Colour figure can be viewed at [wileyonlinelibrary.com](http://wileyonlinelibrary.com)]

**TABLE 2** Difference in Z-scores of CDH fetuses between the first and the last measurement

	FETO	No FETO	p-value
Abdominal circumference ( $\Delta$ Z-score)	0.20 $\pm$ 0.89	0.23 $\pm$ 0.96	0.9
Femur length ( $\Delta$ Z-score)	0.08 $\pm$ 1.24	0.15 $\pm$ 1.03	0.7
Head circumference ( $\Delta$ Z-score)	0.80 $\pm$ 0.80	0.41 $\pm$ 1.23	0.8
Transcerebellar diameter ( $\Delta$ Z-score)	-1.54 $\pm$ 1.95	-1.52 $\pm$ 1.51	1
Lateral cerebral ventricle ( $\Delta$ Z-score)	-0.81 $\pm$ 1.42	-0.56 $\pm$ 1.40	0.4
Middle cerebral artery PI ( $\Delta$ Z-score)	0.76 $\pm$ 1.42	0.74 $\pm$ 1.01	0.9
Middle cerebral artery PSV ( $\Delta$ Z-score)	0.09 $\pm$ 0.76	0.20 $\pm$ 0.70	0.4

Note: Data are given as mean  $\pm$  SD. p-values are derived from an independent t-test.

Abbreviations: CDH, congenital diaphragmatic hernia; PI, pulsatility index; PSV, peak systolic velocity.

in these conditions, left cardiac function is usually impaired.<sup>27,28</sup> It is unlikely that the 10% reduction in MCA PSV would be sufficient to explain the lower cerebellar dimensions. Another contributing factor may be impaired venous return leading to edema which could interfere with normal brain growth. This is supported by increase in extra-axial fluid which was demonstrated by Radhakrishnan et al.; they found on MRI more extra-axial fluid in 57% of CDH fetuses after 28 weeks of gestation, which sharply contrasts with only 2% of fetuses before 28 weeks.<sup>26</sup> Increased axial fluid in CDH has also been reported in the postnatal period.<sup>29,30</sup> It has been hypothesized that, because of the cardiac shift and the cardiac remodeling, the central venous return is impaired, leading to venous hypertension and therefore more extravasation of fluid.<sup>24,31</sup> Another link may be the presence of abnormally narrow veins in the thorax, which has been described in CDH, both in an animal model and clinically.<sup>32,33</sup> A third hypothesis is that there is an underlying common genetic cause for the diaphragmatic defect and impaired cerebellar growth. Although we excluded from our study fetuses with known genetic abnormalities, we did not undertake extensive genetic studies, such

as whole exome sequencing, that could have revealed additional genetic abnormalities. Furthermore, abnormal respiratory ciliary motion has been found to be associated with some forms of brain dysplasia.<sup>34</sup>

In our CDH fetuses the smaller cerebellar dimensions were accompanied by relative smaller ventricles but did not coincide with a lower head size (represented by HC). Conversely, we even observed a trend for a larger HC towards the end of pregnancy. This is consistent with previous ultrasound and MRI studies reporting that in CDH there is a trend for higher BPD Z-scores.<sup>14,26</sup> This apparent contradiction between TCD and HC might be due to regional differences in brain growth. In a series of fetuses with congenital heart disease a reduced brain growth was mainly attributed to lower volume gain of the cortical plate, deep gray and cerebellum.<sup>27</sup> Furthermore an increase of extra-axial CSF might further contribute to a larger HC. It remains uncertain whether and what the clinical implication of the reduced ventricle width is. It may as well be another marker of a decreased brain growth and brain expansion; but this has to be further elucidated.



In our study, fetal biometry and Doppler were not influenced by whether FETO was carried out or not. A previous study reported that fetuses who underwent FETO were born with increased cardiac ventricular dimensions compared to the same severity controls.<sup>35</sup> If that would already occur in utero, this may improve brain perfusion, hence increase biometry. This was not so in our series, but there are several reasons why we may not pick up a difference. For instance, it may be that cardiac changes are too subtle to be measurable on MCA Doppler, or that the interval between FETO and cranial measurements was too short.

The main strengths of our study are first, the large number of fetuses with isolated left-sided CDH and the longitudinal collection of data, which allowed creation of growth curves, and second, this was a multicenter study with many well trained sonographers, which increases its generalizability. The limitations of the study are first, the retrospective analysis of acquired data with the inevitable lack of standardization and the possible selection bias; second, we assumed the MCA PSV to be a proxy for brain perfusion, but flow is a function of both velocity and vessel diameter and we have not measured the latter; and third, we did not have data on postnatal development and therefore we cannot relate our prenatal findings to postnatal outcome. Lastly, ideally we would have normalized the TCD for fetal bodyweight. We avoided to do this because the AC might be reduced in CDH due to herniation of abdominal content into the thorax and because the HC trajectory is altered in CDH. However, given the low number of abnormal AC values (<4% after 28 weeks) we presume the rate of FGR to be low.

## 5 | CONCLUSION

In CDH fetuses, head size was within normal range but the cerebellar diameter trajectory dropped below the fifth percentile after 32 weeks of gestation. The MCA PSV values were consistently lower than in normal fetuses. These observations were correlated with liver herniation and lung size. Our future studies will focus on brain development and link imaging findings to functional outcomes.

## ACKNOWLEDGMENTS

LvdV and DB are funded by the Erasmus + Program of the European Union (Framework Agreement number: 2013-0040). This publication reflects the views only of the authors, and the Commission cannot be held responsible for any use which may be made of the information contained therein. FMR is funded by the KU Leuven (PDM 05/2018). LL is supported by a grant of "Fonds voor Wetenschappelijk Onderzoek" (FWO grantnr 1804718N). JD is receiving support from the Wellcome Trust (WT101957) and Engineering and Physical Sciences Research Council (ESPRC) (NS/A000027/1) and the Great Ormond Street Hospital Charity Fund. EE is funded by (SLT008/18/000156). This research leading to these results was partially funded by Instituto de Salud Carlos III (PI16/00861) integrados en el Plan Nacional de I + D + I y cofinanciados por el ISCIII-Subdirección General de Evaluación y el Fondo Europeo de Desarrollo Regional (FEDER) "Una

manera de hacer Europa", CERCA Programme/Generalitat de Catalunya, "la Caixa" Foundation (LCF/PR/GN14/10270005), AGAUR 2017 SGR grant n° 1531, and The Cerebra Foundation for the Brain-Injured Child, Carmarthen, Wales.

## CONFLICT OF INTEREST

The authors report no conflicts of interest.

## ETHICAL APPROVAL

This study was approved by the Ethics Committee of the University Hospitals Leuven (S56786), Hospital Clínic and Hospital Sant Joan de Deu (PIC-63-20). No specific ethics approval was necessary in the UK for the analysis of retrospective data.

## DATA AVAILABILITY STATEMENT

Data available on request from the authors.

## ORCID

Lennart Van der Veeken  <https://orcid.org/0000-0002-6551-661X>

Francesca M. Russo  <https://orcid.org/0000-0002-5029-7899>

Liesbeth Lewi  <https://orcid.org/0000-0002-9884-5778>

Jan Depreest  <https://orcid.org/0000-0002-4920-945X>

## REFERENCES

1. EUROCAT. EUROCAT Statistical Monitoring Report – 2012. In. 13th February 2015 ed.
2. van den Hout L, Schaible T, Cohen-Overbeek TE, et al. Actual outcome in infants with congenital diaphragmatic hernia: the role of a standardized postnatal treatment protocol. *Fetal Diagn Ther.* 2011;29(1):55-63.
3. Jsselstijn I, Breatnach C, Hoskote A, et al. Defining outcomes following congenital diaphragmatic hernia using standardised clinical assessment and management plan (SCAMP) methodology within the CDH EURO consortium. *Pediatr Res.* 2018;84(2):181-189.
4. Montalva L, Raffler G, Riccio A, Lauriti G, Zani A. Neurodevelopmental impairment in children with congenital diaphragmatic hernia: not an uncommon complication for survivors. *J Pediatr Surg.* 2019;55(4):625-634.
5. Antiel RM, Lin N, Licht DJ, et al. Growth trajectory and neurodevelopmental outcome in infants with congenital diaphragmatic hernia. *J Pediatr Surg.* 2017;52(12):1944-1948.
6. Bevilacqua F, Morini F, Zaccara A, et al. Neurodevelopmental outcome in congenital diaphragmatic hernia survivors: role of ventilatory time. *J Pediatr Surg.* 2015;50(3):394-398.
7. Partridge EA, Bridge C, Donaher JG, et al. Incidence and factors associated with sensorineural and conductive hearing loss among survivors of congenital diaphragmatic hernia. *J Pediatr Surg.* 2014;49(6):890-894.
8. Danzer E, Gerdes M, D'Agostino JA, et al. Longitudinal neurodevelopmental and neuromotor outcome in congenital diaphragmatic hernia patients in the first 3 years of life. *J Perinatol.* 2013;33(11):893-898.
9. Lim JM, Kingdom T, Saini B, et al. Cerebral oxygen delivery is reduced in newborns with congenital heart disease. *J Thorac Cardiovasc Surg.* 2016;152(4):1095-1103.
10. Masoller N, Sanz-Cortés M, Crispí F, et al. Severity of fetal brain abnormalities in congenital heart disease in relation to the main expected pattern of in utero brain blood supply. *Fetal Diagn Ther.* 2016;39(4):269-278.

11. Owen M, Shevell M, Majnemer A, Limperopoulos C. Abnormal brain structure and function in newborns with complex congenital heart defects before open heart surgery: a review of the evidence. *J Child Neurol*. 2011;26(6):743-755.
12. Degenhardt J, Enzensberger C, Tenzer A, et al. Myocardial function pre- and post-fetal endoscopic tracheal occlusion (FETO) in fetuses with left-sided moderate to severe congenital diaphragmatic hernia. *Ultraschall Med*. 2017;38(1):65-70.
13. VanderWall KJ, Kohl T, Adzick NS, Silverman NH, Hoffman JI, Harrison MR. Fetal diaphragmatic hernia: echocardiography and clinical outcome. *J Pediatr Surg*. 1997;32(2):223-226.
14. Kosiv KA, Moon-Grady A, Hogan W, et al. Fetal cerebral vascular impedance is abnormal in left congenital diaphragmatic hernia. *Ultrasound Obstet Gynecol*. 2020;57(3):386-391.
15. Van Mieghem T, Gucciardo L, Done E, et al. Left ventricular cardiac function in fetuses with congenital diaphragmatic hernia and the effect of fetal endoscopic tracheal occlusion. *Ultrasound Obstet Gynecol*. 2009;34(4):424-429.
16. Campbell S, Thoms A. Ultrasound measurement of the fetal head to abdomen circumference ratio in the assessment of growth retardation. *Br J Obstet Gynaecol*. 1977;84(3):165-174.
17. Cardoza JD, Goldstein RB, Filly RA. Exclusion of fetal ventriculomegaly with a single measurement: the width of the lateral ventricular atrium. *Radiology*. 1988;169(3):711-714.
18. Mari G, Deter RL, Carpenter RL, et al. Noninvasive diagnosis by Doppler ultrasonography of fetal anemia due to maternal red-cell alloimmunization. Collaborative Group for Doppler Assessment of the Blood Velocity in Anemic Fetuses. *N Engl J Med*. 2000;342(1):9-14.
19. Salomon LJ, Duyme M, Crequat J, et al. French fetal biometry: reference equations and comparison with other charts. *Ultrasound Obstet Gynecol*. 2006;28(2):193-198.
20. Chavez MR, Ananth CV, Smulian JC, Lashley S, Kontopoulos EV, Vintzileos AM. Fetal transcerebellar diameter nomogram in singleton gestations with special emphasis in the third trimester: a comparison with previously published nomograms. *Am J Obstet Gynecol*. 2003;189(4):1021-1025.
21. Salomon LJ, Bernard JP, Ville Y. Reference ranges for fetal ventricular width: a non-normal approach. *Ultrasound Obstet Gynecol*. 2007;30(1):61-66.
22. Ebbing C, Rasmussen S, Kiserud T. Middle cerebral artery blood flow velocities and pulsatility index and the cerebroplacental pulsatility ratio: longitudinal reference ranges and terms for serial measurements. *Ultrasound Obstet Gynecol*. 2007;30(3):287-296.
23. Van Mieghem T, Sandaite I, Michielsen K, et al. Fetal cerebral blood flow velocities in congenital diaphragmatic hernia. *Ultrasound Obstet Gynecol*. 2010;36(4):452-457.
24. Vogel M, McElhinney DB, Marcus E, Morash D, Jennings RW, Trowetzky W. Significance and outcome of left heart hypoplasia in fetal congenital diaphragmatic hernia. *Ultrasound Obstet Gynecol*. 2010;35(3):310-317.
25. Stressig R, Fimmers R, Eising K, Gembruch U, Kohl T. Preferential streaming of the ductus venosus and inferior caval vein towards the right heart is associated with left heart underdevelopment in human fetuses with left-sided diaphragmatic hernia. *Heart (British Cardiac Society)*. 2010;96(19):1564-1568.
26. Radhakrishnan R, Merhar SL, Burns P, Zhang B, Lim FY, Kline-Fath BM. Fetal brain morphometry on prenatal magnetic resonance imaging in congenital diaphragmatic hernia. *Pediatr Radiol*. 2019;49(2):217-223.
27. Rajagopalan V, Votava-Smith JK, Zhuang X, et al. Fetuses with single ventricle congenital heart disease manifest impairment of regional brain growth. *Prenat Diagn*. 2018;38(13):1042-1048.
28. Olshaker H, Ber R, Hoffman D, Derazne E, Achiron R, Katorza E. Volumetric brain MRI study in fetuses with congenital heart disease. *AJNR Am J Neuroradiol*. 2018;39(6):1164-1169.
29. Danzer E, Zarnow D, Gerdes M, et al. Abnormal brain development and maturation on magnetic resonance imaging in survivors of severe congenital diaphragmatic hernia. *J Pediatr Surg*. 2012;47(3):453-461.
30. Radhakrishnan R, Merhar S, Meinzen-Derr J, et al. Correlation of MRI brain injury findings with neonatal clinical factors in infants with congenital diaphragmatic hernia. *AJNR Am J Neuroradiol*. 2016;37(9):1745-1751.
31. Bulas DI, Taylor GA, O'Donnell RM, Short BL, Fitz CR, Vezina G. Intracranial abnormalities in infants treated with extracorporeal membrane oxygenation: update on sonographic and CT findings. *AJNR Am J Neuroradiol*. 1996;17(2):287-294.
32. Frenckner B, Palmer K, Linden V. Neonates with congenital diaphragmatic hernia have smaller neck veins than other neonates—An alternative route for ECMO cannulation. *J Pediatr Surg*. 2002;37(6):906-908.
33. Luis AL, Bret M, Cuesta E, et al. Microscopic magnetic resonance imaging of the thoracic venous system in rats with congenital diaphragmatic hernia. *Pediatr Surg Int*. 2011;27(2):175-180.
34. Panigrahy A, Lee V, Ceschin R, et al. Brain dysplasia associated with ciliary dysfunction in infants with congenital heart disease. *J Pediatr*. 2016;178:141-148.
35. Rocha LA, Byrne FA, Keller RL, et al. Left heart structures in human neonates with congenital diaphragmatic hernia and the effect of fetal endoscopic tracheal occlusion. *Fetal Diagn Ther*. 2014;35(1):36-43.

**How to cite this article:** Van der Veeken L, Russo FM, Litwinska E, et al. Prenatal cerebellar growth is altered in congenital diaphragmatic hernia on ultrasound. *Prenat Diagn*. 2022;42(3):330-337. <https://doi.org/10.1002/pd.5993>