

Antenatal management of congenital diaphragmatic hernia: What's next ?

Francesca Russo^{1,2}  | Alexandra Benachi³  | Eduard Gratacos⁴  |
 Augusto Zani^{5,6}  | Richard Keijzer⁷  | Emily Partridge⁸  | Nicolas Sananes⁹  |
 Paolo De Coppi¹⁰  | Michael Aertsen¹¹  | Kypros H. Nicolaides¹²  |
 Jan Deprest^{1,2,13} 

¹Department of Development and Regeneration, Cluster Woman and Child, KU Leuven, Leuven, Belgium

²Clinical Department of Obstetrics and Gynaecology, UZ Leuven, Leuven, Belgium

³Department of Obstetrics and Gynaecology, Hospital Antoine Bécélère, Université Paris Saclay, Clamart, France

⁴Hospital Clinic and Sant Joan de Deu, Barcelona, Spain

⁵Division of General and Thoracic Surgery, The Hospital for Sick Children, Toronto, Ontario, Canada

⁶Department of Surgery, University of Toronto, Toronto, Ontario, Canada

⁷Department of Pediatric Surgery, University of Manitoba, Winnipeg, Manitoba, Canada

⁸Department of Pediatric Surgery, Children's Hospital of Philadelphia, Philadelphia, Pennsylvania, USA

⁹Department Obstetrics and Gynaecology, University Hospitals Strasbourg, Strasbourg, France

¹⁰NIHR BRC Great Ormond Street Hospital for Children, London, London, UK

¹¹Department of Radiology, University Hospitals Leuven, Leuven, Belgium

¹²King's College Hospital, London, London, UK

¹³Institute of Women's Health, University College London, London, UK

Correspondence

Jan Deprest, Department of Obstetrics & Gynaecology, University Hospitals Leuven, Herestraat 49 box 7003, B-3000, Leuven, Belgium.
 Email: jan.deprest@uzleuven.be

Funding information

Great Ormond Street Hospital Charity; Engineering and Physical Sciences Research Council, Grant/Award Number: NS/A000027/1

Abstract

Congenital diaphragmatic hernia can be diagnosed in the prenatal period and its severity can be measured by fetal imaging. There is now level I evidence that, in selected cases, Fetoscopic Endoluminal Tracheal Occlusion with a balloon increases survival to discharge from the neonatal unit as well as the risk for prematurity. Both effects are dependent on the time point of tracheal occlusion. Fetoscopic Endoluminal Tracheal Occlusion may also lead to iatrogenic death when the balloon cannot be timely retrieved. The implementation of the findings from our clinical studies, may also vary based on local conditions. These may be different in terms of available skill set, access to fetal therapy, as well as outcome based on local neonatal management. We encourage prior benchmarking of local outcomes with optimal post-natal management, based on large enough numbers and using identical criteria as in the recent trials. We propose to work further on prenatal prediction methods, and the improvement of fetal intervention. In this manuscript, we describe a research agenda from a fetal medicine perspective. This research should be in parallel with innovation in neonatal and pediatric (surgical) management of this condition.

Kypros H. Nicolaides and Jan Deprest have contributed equally to this manuscript.

Key points**What is already known about this topic ?**

- Congenital diaphragmatic hernia (CDH) can be diagnosed and its severity assessed in the prenatal period.
- In fetuses with severe or moderate pulmonary hypoplasia, fetal surgery can be offered.
- In selected cases, Fetoscopic Endoluminal Tracheal Occlusion (FETO) improves survival but increases the risk for prematurity.

What does this study add?

- Further research into accurate prenatal prediction of outcome is needed and the best biomarkers should be identified.
- We propose prospective registration of cases treated with FETO, to increase our understanding of the effect of the duration of occlusion and the potential impact of preterm delivery.
- Outcomes of fetal surgery should improve further, both by technical innovation in the current technique as well as the introduction of additional and more effective therapies.

1 | INTRODUCTION

Congenital diaphragmatic hernia (CDH) is a good target condition for fetal therapy, as it originates prenatally and results in severe postnatal mortality and morbidity, which have not improved significantly over the last decade despite advances in neonatal care. Neonatal survival rates have stalled at around 70%.¹ Many research teams have explored strategies to stimulate growth and maturation of airways and pulmonary vessels, initially by prenatal anatomical repair of the diaphragmatic defect through hysterotomy, and later by fetal tracheal occlusion.² In the early 21st century, the concept of tracheal occlusion moved from the *animal* experimental laboratory towards early *clinical* application, and from *external* tracheal clipping by hysterotomy³ to *endoluminal* occlusion (FETO) with a detachable balloon.⁴ The latter allowed this procedure to be done percutaneously under local anesthesia, and facilitated its in utero reversal.⁵ Table 1 summarizes some of that Odyssey, illustrating the steps our group has taken to eventually tick all the boxes of the *fetal surgery check-list* defined by the International Fetal Medicine and Surgery Society.⁶

However, many questions persist around the management of CDH today, and practice may need to vary depending on pre- and postnatal facilities as well as on the scientific evidence becoming available over time. Here, we highlight some of these issues and describe how we plan to address some of these, using current and technology. We also highlight emerging technologies and new therapeutic approaches that may help improve both prediction of outcome and outcome itself. We are aware that, as fetal medicine specialists and being deeply involved in the development of fetoscopy, we may be biased in our views. We also acknowledge the major contributions of other research teams and innovations in pediatric surgery and neonatal and pediatric care.

2 | WHAT ARE OUTCOMES WITH FETOSCOPIC ENDOLUMINAL TRACHEAL OCCLUSION TODAY ?

Two decades of research involving FETO culminated in the publication of the results of two parallel randomized controlled trials in isolated left-sided CDH with severe and moderate pulmonary hypoplasia, respectively (Table 2).^{7,8} In severe hypoplasia the balloon was inserted *early* (27⁺⁰ to 29⁺⁶ weeks' gestation) and FETO improved survival from 15% to 40%.⁸ A very similar improvement in survival (20% to 42%) was achieved in a non-randomized study of severe *right-sided* CDH treated with FETO at a comparable gestational age, by comparison to a parallel cohort of fetuses managed postnatally.⁹ In *moderate* hypoplasia the balloon was inserted *late* (30⁺⁰ to 31⁺⁶ weeks' gestation) in an effort to reduce the risks of very preterm birth. In that study, FETO improved survival from 50% to 63%, but this difference was not statistically significant.⁷ Analysis of the pooled data from the severe and moderate hypoplasia trials suggest that FETO increases survival in both severe and moderate disease (Table 2; Figure 1a en 1b), but the observed lesser effect in the moderate group was a mere consequence of the delayed insertion of the balloon.¹⁰

An adverse consequence of FETO in both Tracheal Occlusion To Accelerate Lung growth (TOTAL)-trials, which was also observed in other clinical studies was the increased risk for iatrogenic preterm membrane rupture and preterm birth.^{11,12} In the TOTAL trials this risk was inversely related to the gestational age at insertion of the balloon (Figure 1c).¹⁰ Although the trials did not demonstrate any significant differences between the FETO and control groups in prematurity related complications, they were not powered for these secondary outcomes. Furthermore, we have not yet reported long term outcome as we are in the process of collecting such data.

TABLE 1 Scorecard for fetal therapy for Congenital diaphragmatic hernia (CDH). Criteria for fetal surgery as defined by the International Fetal Medicine and Surgery Society (first column), contributions by FETO-consortium towards the clinical introduction of Fetoscopic Endoluminal Tracheal Occlusion (FETO) (second column) and future research into the antenatal management of isolated CDH

| | Work done within this consortium | Possible future actions |
|--|---|---|
| Diagnosis must be made with certainty and additional anomalies excluded | Up to two thirds of cases are picked up in screening programs by the second trimester ⁶³ | Increase awareness, quality control, teaching in early diagnosis, use of advanced genetic testing to rule out underlying problems |
| Natural history must be predictable treatment cannot wait Postnatal treatment not effective enough | Reproducible methods of lung measurement in normal and hernia fetuses using ultrasound and MRI (reviewed in ⁸¹) | Validating prediction by medical imaging |
| | Other parameters: liver and stomach position | Define novel biomarkers, preferentially usable early in pregnancy and/or correlating with response to fetal therapy |
| | Defining severe pulmonary hypoplasia | Improving prediction mortality by combining biomarkers |
| | Consensus standardized prenatal assessment ⁶⁴ | |
| Experimental basis of fetal intervention available | Tracheal occlusion in lambs: Fetoscopic technique ⁸²⁻⁸⁴ and relevance of prenatal reversal (Plug-Unplug Sequence) ⁸⁵ | More potent intervention: Preclinical studies with medical adjuncts and/or novel strategies |
| Treatment offered within clinical trials by multidisciplinary teams | First in woman study ⁴ | Systematic reviews |
| | Prospective cohorts ^{15,25,86} | Prospective registries |
| | Standardized neonatal management ^{87,88} and counseling ⁸⁹ | Controlled trials where that is possible |
| | Contemporary controlled cohorts right CDH ⁹ | Definition of core outcome set ¹⁹ |
| | Randomized controlled trials in left CDH ^{7,8} | Health technology assessment |
| | Pooled analysis of data ¹⁰ | |
| (Maternal safety) | Documentation of (1) nature and incidence severe complications ⁹⁰ and (2) of reproductive and psychological outcomes ⁶⁰ | Defining patient needs in fetal therapy programs, determine acceptability of future alternative therapies |

Note: Go to text on Table 1.

TABLE 2 Outcomes of fetuses diagnosed with isolated Congenital diaphragmatic hernia (CDH) in the prenatal period, either left or right sided, expectantly managed during pregnancy or having tracheal occlusion in the Tracheal Occlusion To Accelerate Lung growth (TOTAL) trial, as well as an analysis and modeling based on the pooled data, as well as a large study on right sided CDH under the same management protocol

| Side, severity | Criteria severity on ultrasound | Survival to discharge | | |
|--|---|-----------------------|--------------|------------------------|
| | | Expectant | FETO | RR (95% CI) |
| Isolated left sided CDH – TOTAL trials | | | | |
| TOTAL severe ⁸ | O/E LHR <25.0% Irrespective of liver position | 6/40 (15%) | 16/40 (40%) | 2.67 (1.22-6.11) |
| TOTAL moderate ⁷ | O/E LHR 25.0%–34.9%, any liver position O/E LHR 35.0%–44.9% & liver into chest | 49/98 (50%) | 62/98 (63%) | 1.27 (0.99-1.63) |
| Isolated left sided CDH – Pooled analysis TOTAL data ¹⁰ | | | | |
| Late insertion | O/E LHR 0.0%–34.9%, any liver position O/E LHR 35.0%–44.9% & liver into chest | 55/142 (39%) | 79/145 (54%) | A or: 1.78 (1.05-3.01) |
| Early insertion | O/E LHR 0.0%–34.9%, any liver position O/E LHR 35.0%–44.9% & liver into chest | | | A or: 2.73 (1.15-6.49) |
| Isolated right sided CDH | | | | |
| Severe ⁹ | O/E LHR <50% Irrespective of liver position | 7/34 (20%) | 53/125 (42%) | 2.84 (1.15-7.01) |

Abbreviations: CI, Confidence Interval; RR, Relative Risk.

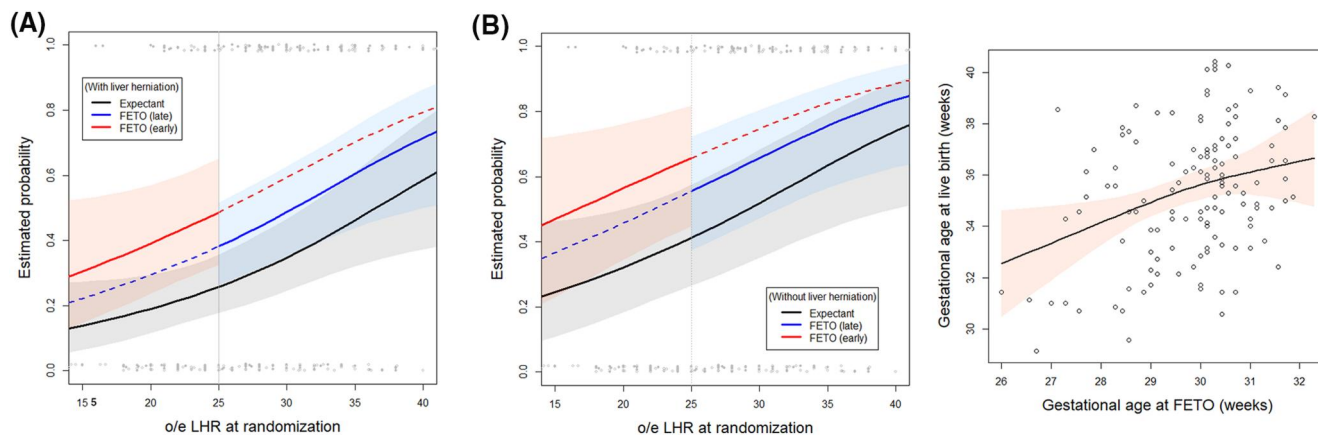


FIGURE 1 Estimated probabilities of survival to discharge based on a model, for cases with liver herniation (A) or with the liver confined to the abdomen (B). Dashed red and blue lines indicate situations that are not included in the Tracheal Occlusion To Accelerate Lung growth trials: early insertion in moderate hypoplasia and late insertion in severe hypoplasia. C, Estimated gestational age at live birth as a function of gestational age at Fetoscopic Endoluminal Tracheal Occlusion (FETO), with pointwise 95% confidence intervals. Pointwise 95% confidence intervals are added as shaded areas. Raw patient data are indicated on top (survivors) and at the bottom (non-survivors) of the plot. Reproduced, with permission from the authors and the publisher.¹⁰ [Colour figure can be viewed at wileyonlinelibrary.com]

3 | PRACTICAL IMPLEMENTATION FETOSCOPIC ENDOLUMINAL TRACHEAL OCCLUSION

Completion of the TOTAL trials was considered to be a major achievement, but soon concerns were raised as to the possible widespread implementation of FETO.^{13,14} This is part of the debate elsewhere in this issue of *Prenatal Diagnosis*.¹⁴ An important concern with wide implementation is the risk of perinatal death because of problems with timely removal of the tracheal balloon.¹⁵ Consequently, FETO should only be undertaken in specialist centers, which, according to our criteria, should have extensive experience in fetoscopy, have a sufficient volume of CDH cases, be familiar with assessment of severity of pulmonary hypoplasia,¹⁶⁻¹⁸ and be trained with balloon insertion and removal, with the latter service being available 24 h a day, 7 days a week.¹⁵ To our knowledge there is no other fetal procedure posing such extensive demands on the treatment team.

4 | THE NATURAL HISTORY OF CONGENITAL DIAPHRAGMATIC HERNIA IS QUESTIONED

A criticism of the TOTAL trials is that the mortality in the expected management group was higher than what was reported "in other environments such as North America, where major advances in postnatal care involving respiratory care strategies based on permissive hypercapnia/spontaneous ventilation and extracorporeal life support have generated significantly improved outcomes in prenatally stratified, severe CDH patients".¹³ The authors of this statement refer to studies from 1995 to 1997, a time when a validated model for prenatal severity stratification was not available. Furthermore, the authors refer in their letter to the benefits of postnatal management approaches, such as specific ventilation strategies, extra-corporeal

membrane oxygenation and others, for which to our knowledge there is no robust and unbiased controlled data to support such statements. We are sure these strategies have had and will continue to have their place in the further search to improve survival, but it is difficult to use these in an argument against a study where a standardized postnatal management was applied for both arms of the randomized controlled trial. However, we hear the argument that some postnatal management studies do indeed report higher survival rates than those observed in our trial, hence these patients may not benefit as much from FETO. It must be remembered that the numbers reported in the TOTAL trial included cases with additional anomalies diagnosed postnatally, terminations and in utero fetal deaths.

It is therefore indeed possible (and perhaps to be recommended) that when counselling patients, centers that expect high survival rates with postnatal management, "validate" the prediction algorithm and adjust to that accordingly. It is important to remember that prediction algorithms are only meaningful on large numbers and consecutive cases, all selected the same way as in the prediction studies (i.e. prenatal diagnosis, standardized severity assessment in the second or early third trimester, live born after 30 weeks and all managed with a standardized postnatal protocol) and reporting all core outcomes.¹⁹ For example, fetal surgeons from Queretaro,^{20,21} Mexico concluded that in their setting with suboptimal neonatal management, the postnatal outcome of CDH is less favourable than that observed elsewhere. The same was earlier reported in a study from Brazil.²² Whether these very low postnatal survival rates should be improved by an antenatal intervention is another discussion; some reflection on the postnatal management may be useful.²³ Regardless, the TOTAL trial survival rates in expectantly managed cases were consistent with our previous observational data and with the results from one randomized clinical trial among neonatal management centers throughout Europe.²⁴⁻²⁶ For instance, in fetuses with

expectantly managed severe hypoplasia, survival rate was 15%, which compares to the 18% anticipated.²⁷ Given the latter, we feel confident to continue the FETO program with the current selection criteria. We will sustain the surveillance system with prospective documentation of outcomes, and we will strive to establish long term follow up.

5 | FETOSCOPIC ENDOLUMINAL TRACHEAL OCCLUSION IN MODERATE HYPOPLASIA ?

The conclusion from the analysis of the combined data from the two TOTAL trials is that treatment of the moderate hypoplasia group is most likely to be beneficial, provided the duration of tracheal occlusion would be extended. The latter can be achieved by either earlier insertion or delayed removal of the balloon.¹⁰ Delay in removal of the balloon from 34 to 37 weeks is not currently an option because of the increased risks associated with emergency removal in women with ruptured membranes and/or in labour. Moreover, there is some evidence that survival rates are higher in patients where the balloon is removed more than 24 h prior to delivery.^{7,15,28,29} There is also some evidence that the beneficial effects of FETO are less late in pregnancy, because of limited lung growth.^{30,31} Therefore, the alternative option is to carry out FETO in both severe and moderate hypoplasia at 27⁺⁰ to 29⁺⁶ weeks. Although early insertion in moderate hypoplasia would best be evaluated in a randomized controlled trial, in our opinion and based on our experience, a new randomized clinical trial is unrealistic.^{10,32-38} As a second best option to evaluate such strategy, we have chosen to prospectively register all consecutive cases undergoing FETO, including all known confounding factors.³⁷ We will include registration of additional factors that are potentially related to outcome, such as the location, experience and case load of the postnatal management center.^{39,40} Because new centers may not apply similar scrutiny as TOTAL-trial fetal surgeons, all local modifications in the protocol should be documented. Nonetheless, we recommend that this type of fetal intervention be not offered outside of the context of this program.

6 | IMPROVEMENTS IN FETAL SURGERY

Reduction in FETO-related adverse outcomes could be achieved with technical improvements in endoscopy and occlusion devices. We aim to achieve further miniaturization of the endoscopes, but working on instrumentation has become increasingly difficult due to the (unintended) consequences of the new Medical Device Regulation in Europe. We have successfully completed preclinical studies with the “Smart-TO”-balloon (BS Medical Tech Industry, Niederroedern, France; Figure 2).⁴¹ This balloon has a magnetic valve that opens by exposure to a strong magnetic field, that is the fringe field around an magnetic resonance imaging (MRI) scanner. After deflation, the balloon is either swallowed by the fetus or exits the mouth into the amniotic fluid. Tests in large animal models confirmed that this device



FIGURE 2 Smart-TO™ device, uninflated (left) and inflated with 0.7 mL saline (right). This is an experimental tracheal occlusion device with similar dimensions as the device used so far, but with a magnetic valve. This permits non-invasive opening of the valve by exposure to the fringe field of a clinical magnetic resonance imaging device.⁴¹ Copyright of and reproduced with permission of the manufacturer. [Colour figure can be viewed at wileyonlinelibrary.com]

has similar occlusive and tracheal side effects as the currently used “Goldbal” balloon (Balt, Montmorency, France) and that it spontaneously releases after MRI exposure.⁴¹⁻⁴³ In Leuven and Paris, we have moved to the “first-in-human” trial, aiming to demonstrate the feasibility to deflate the balloon by exposing the fetus to the magnetic field generated by a clinical MRI scanner. This is a step towards obtaining C.E. approval for this medical device. If effective, using this balloon will eliminate the second invasive intervention, lower the burden on patients as well as the team, making FETO safer and thus more acceptable.

7 | MEDICAL STRATEGIES TO TREAT PULMONARY HYPOPLASIA

Given the suboptimal outcomes and risks of the current surgical technique, alternative strategies to promote airway growth and reverse pulmonary artery changes are needed. We are exploring medical interventions, that would preferentially be administered transplacentally. We moved one of these already from the bench to the bedside. *Sildenafil* is a selective inhibitor of phosphodiesterase type 5 and has vasodilatory and anti-remodelling effects on the pulmonary circulation. It is used for the treatment of neonatal pulmonary hypertension (PHT) including in CDH.⁴⁴ Based on its effectiveness in three animal models of CDH⁴⁵ we conducted a phase I-IIIb trial in pregnant women.⁴⁶ Unfortunately, these trials were halted by the authorities because findings in the “Sildenafil TheRapy In Dismal prognosis Early onset fetal growth Restriction” (STRIDER) clinical trial suggested a risk of increased incidence of PHT in neonates who were exposed to sildenafil *in-utero*. This observation was limited to a single regional arm of the larger trial. We have argued that this observation in fetuses with normal lungs should not be extrapolated to CDH fetuses who have pulmonary hypoplasia and abnormal pulmonary vascular development. Several animal studies demonstrated that the vascular effects depend on the degree of lung development, hence can be beneficial or adverse.^{47,48} Both fetal rats and rabbits with *pulmonary hypoplasia* show improved lung vasculature when exposed to sildenafil, whereas fetuses with *normal* lungs show abnormal vascular branching. We have requested permission to carry

out further research on the use of sildenafil in pregnant women, but at present this has not been approved.^{49,50}

An alternative drug for transplacental administration to treat abnormal vascular development is *treprostinil*, which is a synthetic prostacyclin analog. It is clinically approved for the treatment of PHT in adults and children but has only been tested in small patient cohorts.^{51,52} It has an anti-remodeling effect on the pulmonary vasculature in addition to causing pulmonary vasodilation. Treprostinil is not teratogenic and we are now trialing it preclinically for in utero use for CDH in collaboration with researchers from the Children's Hospital of Philadelphia.⁵³

Another exciting potentially more comprehensive approach may be the fetal pulmonary administration of amniotic fluid stem cell-derived extracellular vesicles. EVs are biological nanoparticles carrying genetic material and bioactive proteins as cargo. In fact, EVs are mediators of Amniotic Fluid derived Stem Cells (AFSC) paracrine signaling and promote lung development and maturation, as shown in multiple models of pulmonary hypoplasia (primary epithelial cells, organoids, explants, and two animal models).⁵⁴ Zani summarizes that journey in this issue of Prenatal Diagnosis.⁵⁵

Finally, excitement has been growing on the potential of using non-coding RNAs to improve diagnosis, prognosis and prenatal therapy for CDH. MicroRNAs are small, non-coding RNAs that can regulate the expression of genes. MicroRNA miR-200b has been demonstrated to be more abundantly present in the tracheal fluid of CDH survivors after FETO.⁵⁶ Knockout mouse studies showed that miR-200b is required for distal airway development and pulmonary epithelial integrity.⁵⁷ And most clinically relevant, prenatal miR-200b therapy reduces the incidence of CDH and improves lung development resulting in better survival in the nitrofen-induced rat model of CDH.⁵⁸ MicroRNAs are regulated by circular RNAs (circRNAs) through sequestration. CircRNAs are formed by "back-to-back" splicing and their circular structure protects them from degradation in biological compartments. Because of their biostability they are considered the "perfect disease biomarker". Congenital diaphragmatic hernia lungs have a unique circRNA profile distinguishing them from control lungs.⁵⁹ We have recently discovered that CDH fetuses undergoing FETO with identical prognostic imaging parameters, can be discriminated from future survivors and non-survivors based on their amniotic fluid circRNA profile before FETO (unpublished data). This suggests that circRNAs can serve as an important prognostic biomarker for pulmonary hypoplasia in CDH and we are currently validating these findings in independent patient cohorts. In contrast to microRNAs, the potential role of circRNAs in the pathogenesis and in prenatal therapy has not been demonstrated and is currently under investigation.

8 | PATIENT ENGAGEMENT AND POSTNATAL TRIALS

Further to therapeutic innovation, the advent of fetal surgery as an option for parents prompts the question about the needs of these families. We need to investigate whether the current antenatal care

pathway is holistic, patient-centered, supports families in all prenatal and postnatal options, and generally meets patient needs.⁶⁰ To facilitate this, we have developed a core set of outcomes to be used in future trials on perinatal interventions for CDH¹⁹ in collaboration with parents and other stakeholders. These will be measured in a standardized manner and reported consistently, thereby improving the quality of research that can be used to guide clinical practice and improve patient care.

All research efforts to improve prenatal management should be paralleled by similar efforts in postnatal management research. Obstetricians may get involved in trials which already start at birth. We are aware of two clinical trials investigating whether delayed cord clamping facilitates neonatal cardiovascular adaptation.⁶¹ This should prevent early hypoxemia, increase circulatory blood volume and avoid loss of venous return and decrease in left ventricle filling, which is caused by immediate cord clamping (CHIC trial, NCT04429750 & Physiological-based Cord Clamping in CDH, PinC, NCT04373902).⁶²

9 | DIAGNOSIS AND PREDICTION OF OUTCOME IN CONGENITAL DIAPHRAGMATIC HERNIA

In order to have treatment options in the prenatal period, the diagnosis of CDH should be made prenatally. Today, screening ultrasound programs fail to diagnose CDH in nearly one out of three cases. This needs to be improved.⁶³ Once the diagnosis is made, ideally *personalized* prediction is made based on an expert assessment. In Europe, the reference network for rare diseases "ERNICA" has agreed on a standardized method.⁶⁴ Prediction of outcome is made by determination of lung size, position of the liver and can also include the position of the stomach as a proxy for liver position. The most used, best validated and widely implemented method for measurement of lung size is based on *two-dimensional ultrasound* measurement of the lung area contralateral to the defect, divided by the head circumference (observed Lung-Head Ratio; LHR), and corrected for gestational age by expressing the observed LHR as a percentage of the LHR *expected* in a normal fetus (*observed/expected* lung-to-head ratio or "O/E LHR").²⁷ The combination of O/E LHR and liver position is used to categorize fetuses with left sided CDH as having either severe, moderate or mild hypoplasia; this corresponds with survival chances of 18%, $\geq 60\%$ and $\geq 85\%$ respectively.²⁷ In right-sided CDH, a rarer subtype of CDH with a worse prognosis, liver position is irrelevant. According to a recent large study, an O/E LHR of 50% corresponds with a 20% survival rate.⁹ There are several criticisms of the currently used prediction model. One is that it is based on limited and historical data and may therefore benefit from more, contemporary and unbiased data. Even the normative curve can be improved, as it was originally based on cross sectional data, and from a statistical viewpoint it may benefit from more and preferentially longitudinal observations.

A potentially better way of assessing lung size is to use *three-dimensional* ultrasound to determine the volume of both lungs. However, although possible, this approach is difficult to perform and

not consistently reliable.^{65,66} Use of MRI can provide reliable measurements of lung volumes and can also report the volume of liver in the chest as a continuous variable, rather than “up” or “down” as with ultrasound, and document stomach position as well.^{67,68} A previous study reported that the predictive performance of the ultrasound derived o/eLHR was not significantly different to that of the MRI derived o/e total lung volume, in terms of postnatal survival. This was done in 76 fetuses with isolated CDH that were all liveborn at 30 weeks' gestation.⁶⁹ It is possible that a larger study may demonstrate the superiority on the one technique over the other. Also, 3D-volumetry is time consuming and prone to errors, a problem which can be resolved by using artificial intelligence. Artificial intelligence approaches have solved many previously intractable medical image segmentation problems, but *fetal* MRI still relies on manual segmentations from motion-corrupted stacks of 2D slices. We have used this approach already for the brain and are now implementing it on lung measurements.^{70,71}

The second most important cause of death in babies with CDH, after pulmonary hypoplasia, is PHT⁷² and presently there is no effective method to predict this adverse outcome.^{29,73} Other goals for research in CDH fetuses are the study of the fetal heart and brain. Neurodevelopmental delay, hearing, learning and behavioral problems have been reported in up to 16% of children with *isolated CDH*⁷⁴ and *postnatal* MRI studies demonstrated abnormalities such as delayed sulcation and white matter injury.⁷⁵⁻⁷⁷ This may be due to postnatal events but could also originate in utero, as has been observed in fetuses with cardiopathies,^{78,79} and recently suggested for cerebellar development in CDH fetuses.⁸⁰

10 | RARER AND ASSOCIATED FORMS OF CONGENITAL DIAPHRAGMATIC HERNIA

In many studies, reported outcomes still mix those of fetuses with isolated CDH and CDH associated with chromosomal anomalies or other structural malformations. This should be avoided as the prognosis of non-isolated cases is obviously different and difficult to predict. We also suggest that outcomes of fetuses with isolated *left* and *right* diaphragmatic hernia should always be reported separately, and this should also be done for other rarer anatomical forms of CDH as the pathophysiology of all these specific anatomical variations is most likely to be different. For prenatal prediction of prognosis one can therefore not use the same algorithm.

Fetuses that are thought to have isolated CDH, including those who are offered FETO, may later be found to have an associated structural malformation, rare genetic diseases or chromosomal anomalies. These conditions may be identified prenatally but occasionally the diagnosis may not become apparent until several months after birth. We have observed this both in our earlier experience as well as in the TOTAL trials.^{7,8,25} Parents should be informed that this may happen and that it may have severe consequences for their child. As to associated genetic conditions, recent improvements in the accuracy of genetic tests such as exome

sequencing should limit the risk of an diagnosed genetic association. When and where that testing will be implemented is another issue, which is out of the scope of this comment. The value of FETO in cases of associated genetic problems is uncertain. The decision to proceed with FETO will depend on the nature of the individual case, the wishes of the parents, even in cases of severe genetic conditions, and the local context.

11 | CONCLUSION

There is now level I evidence that in utero treatment can improve outcome in selected fetuses with CDH. Inevitably, more fetal centers are likely to now offer this therapy. However, the number of eligible fetuses for such therapy is low and it would be wise to limit the procedure to units with extensive experience in fetal assessment and fetoscopy, as well as high level of neonatal and pediatric surgical care and for further multidisciplinary management of these overall rare cases. Further studies are necessary to first, define the impact of preterm birth on FETO survivors, second, examine the impact of early rather than late tracheal occlusion in fetuses with moderate hypoplasia, third, develop improved models for prenatal prediction of outcome, fourth, improve instrumentation to reduce procedure-related complications, and, finally, explore promotion of lung growth with additional or alternative fetal therapies.

ACKNOWLEDGMENT

We acknowledge the funders of the research into CDH at KU Leuven, that is the Flanders Research Foundation (FWO Vlaanderen; 1.8.012.07), the GOSH Children's Charity, Congenital Diaphragmatic Hernia UK., the Wellcome Trust (WT101957) and the Engineering and Physical Sciences Research Council (NS/A000027/1). JD is funded by the Great Ormond Street Hospital Charity Fund. PDC is partially supported by the Great Ormond Street Hospital NIHR Biomedical Research Centre. The views expressed are those of the author(s) and not necessarily those of the NIHR or the Department of Health.

CONFLICT OF INTEREST

The authors report no conflicts of interest.

DATA AVAILABILITY STATEMENT

This paper does not report on any original data.

ORCID

Francesca Russo  <https://orcid.org/0000-0002-5029-7899>

Alexandra Benachi  <https://orcid.org/0000-0001-6045-0765>

Eduard Gratacos  <https://orcid.org/0000-0002-7405-7224>

Augusto Zani  <https://orcid.org/0000-0003-2283-9846>

Richard Keijzer  <https://orcid.org/0000-0002-0108-3157>

Emily Partridge  <https://orcid.org/0000-0002-0619-1843>

Nicolas Sananes  <https://orcid.org/0000-0002-0461-8428>

Paolo De Coppi  <https://orcid.org/0000-0002-1659-0207>

Michael Aertsen  <https://orcid.org/0000-0003-1994-5365>

Kypros H. Nicolaidis  <https://orcid.org/0000-0003-1266-0711>

Jan Deprest  <https://orcid.org/0000-0002-4920-945X>

REFERENCES

- Gupta VS, Harting MT, Lally PA, et al. Mortality in congenital diaphragmatic hernia: a multicenter registry study of over 5000 patients over 25 years. *Ann Surg*. 2021.
- Deprest JA, Flake AW, Gratacos E, et al. The making of fetal surgery. *Prenat Diagn*. 2010;30(7):653-667.
- Flake AW, Crombleholme TM, Johnson MP, Howell LJ, Adzick NS. Treatment of severe congenital diaphragmatic hernia by fetal tracheal occlusion: clinical experience with fifteen cases. *Am J Obstet Gynecol*. 2000;183(5):1059-1066.
- Deprest J, Gratacos E, Nicolaidis KH, Group FT. Fetoscopic tracheal occlusion (FETO) for severe congenital diaphragmatic hernia: evolution of a technique and preliminary results. *Ultrasound Obstet Gynecol*. 2004;24(2):121-126.
- Van der Veecken L, Russo FM, De Catte L, et al. Fetoscopic endoluminal tracheal occlusion and reestablishment of fetal airways for congenital diaphragmatic hernia. *Gynecol Surg*. 2018;15(1):9.
- Harrison MR, Filly RA, Golbus MS, et al. Fetal treatment 1982. *N Engl J Med*. 1982;307(26):1651-1652.
- Deprest JA, Benachi A, Gratacos E, et al. Randomized trial of fetal surgery for moderate left diaphragmatic hernia. *N Engl J Med*. 2021;385(2):119-129.
- Deprest JA, Nicolaidis KH, Benachi A, et al. Randomized trial of fetal surgery for severe left diaphragmatic hernia. *N Engl J Med*. 2021;385(2):107-118.
- Russo FM, Cordier AG, Basurto D, et al. Fetal endoscopic tracheal occlusion reverses the natural history of right-sided congenital diaphragmatic hernia: European multicenter experience. *Ultrasound Obstet Gynecol*. 2021;57(3):378-385.
- Van Calster B, Benachi A, Nicolaidis KH, et al. The randomized TOTAL-trials on fetal surgery for congenital diaphragmatic hernia: re-analysis using pooled data. *Am J Obstet Gynecol*. 2021.
- Araujo Junior E, Tonni G, Martins WP, Ruano R. Erratum: procedure-related complications and survival following fetoscopic endotracheal occlusion (FETO) for severe congenital diaphragmatic hernia: systematic review and meta-analysis in the FETO era. *Eur J Pediatr Surg*. 2017;27(4):e1.
- Araujo Junior E, Tonni G, Martins WP, Ruano R. Procedure-related complications and survival following fetoscopic endotracheal occlusion (FETO) for severe congenital diaphragmatic hernia: systematic review and meta-analysis in the FETO era. *Eur J Pediatr Surg*. 2017;27(4):297-305.
- Stolar CJH, Flake AW, Losty PD. Fetal surgery for severe left diaphragmatic hernia. *N Engl J Med*. 2021;385(22):2111-2112.
- Deprest J, Flake A. How should fetal surgery for congenital diaphragmatic hernia be implemented in the post-TOTAL trial era: a discussion. *Prenat Diagn*. 2022.
- Jimenez JA, Eixarch E, DeKoninck P, et al. Balloon removal after fetoscopic endoluminal tracheal occlusion for congenital diaphragmatic hernia. *Am J Obstet Gynecol*. 2017;217(1):78.e71-78.e11.
- Cruz-Martinez R, Figueras F, Moreno-Alvarez O, et al. Learning curve for lung area to head circumference ratio measurement in fetuses with congenital diaphragmatic hernia. *Ultrasound Obstet Gynecol*. 2010;36(1):32-36.
- Abbasi N, Cortes MS, Ruano R, et al. Variability in antenatal prognostication of fetal diaphragmatic hernia across the North American Fetal Therapy Network (NAFTNet). *Prenat Diagn*. 2020;40(3):342-350.
- Abbasi N, Ryan G, Johnson A, et al. Reproducibility of fetal lung-to-head ratio in left diaphragmatic hernia across the North American Fetal Therapy Network (NAFTNet). *Prenat Diagn*. 2019;39(3):188-194.
- Vergote S, De Bie F, Bosteels J, et al. Study protocol: a core outcome set for perinatal interventions for congenital diaphragmatic hernia. *Trials*. 2021;22(1):158.
- Cruz-Martinez R, Martinez-Rodriguez M, Gamez-Varela A, et al. Survival outcome in severe left-sided congenital diaphragmatic hernia with and without fetal endoscopic tracheal occlusion in a country with suboptimal neonatal management. *Ultrasound Obstet Gynecol*. 2020;56(4):516-521.
- Cruz-Martinez R, Shazly S, Martinez-Rodriguez M, et al. Impact of fetal endoscopic tracheal occlusion in fetuses with congenital diaphragmatic hernia and moderate lung hypoplasia. *Prenat Diagn*. 2021.
- Ruano R, Yoshisaki CT, da Silva MM, et al. A randomized controlled trial of fetal endoscopic tracheal occlusion versus postnatal management of severe isolated congenital diaphragmatic hernia. *Ultrasound Obstet Gynecol*. 2012;39(1):20-27.
- Jani JC, Nicolaidis KH. Fetal surgery for severe congenital diaphragmatic hernia? *Ultrasound Obstet Gynecol*. 2012;39(1):7-9.
- Done E, Gratacos E, Nicolaidis KH, et al. Predictors of neonatal morbidity in fetuses with severe isolated congenital diaphragmatic hernia undergoing fetoscopic tracheal occlusion. *Ultrasound Obstet Gynecol*. 2013;42(1):77-83.
- Jani JC, Nicolaidis KH, Gratacos E, et al. Severe diaphragmatic hernia treated by fetal endoscopic tracheal occlusion. *Ultrasound Obstet Gynecol*. 2009;34(3):304-310.
- Snoek KG, Capolupo I, van Rosmalen J, et al. Conventional mechanical ventilation versus high-frequency oscillatory ventilation for congenital diaphragmatic hernia: a randomized clinical trial (the VICI-trial). *Ann Surg*. 2016;263(5):867-874.
- Jani J, Nicolaidis KH, Keller RL, et al. Observed to expected lung area to head circumference ratio in the prediction of survival in fetuses with isolated diaphragmatic hernia. *Ultrasound Obstet Gynecol*. 2007;30(1):67-71.
- Deprest J, Nicolaidis K, Done E, et al. Technical aspects of fetal endoscopic tracheal occlusion for congenital diaphragmatic hernia. *J Pediatr Surg*. 2011;46(1):22-32.
- Done E, Gratacos E, Nicolaidis K, et al. Predictors of neonatal morbidity in fetuses with severe isolated congenital diaphragmatic hernia undergoing fetoscopic tracheal occlusion. *Ultrasound Obstet Gynecol*. 2013.
- Nawapun K, Eastwood MP, Diaz-Cobos D, et al. In vivo evidence by magnetic resonance volumetry of a gestational age dependent response to tracheal occlusion for congenital diaphragmatic hernia. *Prenat Diagn*. 2015;35(11):1048-1056.
- Cannie MM, Jani JC, De Keyzer F, Allegaert K, Dymarkowski S, Deprest J. Evidence and patterns in lung response after fetal tracheal occlusion: clinical controlled study. *Radiology*. 2009;252(2):526-533.
- Basurto D, Russo FM, Van der Veecken L, et al. Prenatal diagnosis and management of congenital diaphragmatic hernia. *Best Pract Res Clin Obstet Gynaecol*. 2019;58:93-106.
- Ville Y. Should we offer fetal surgery for severe congenital diaphragmatic hernia or bring these cases to trial? Difference between chance and hazard. *Ultrasound Obstet Gynecol*. 2020;56(4):491-492.
- Deprest J. Prenatal treatment of severe congenital diaphragmatic hernia: there is still medical equipoise. *Ultrasound Obstet Gynecol*. 2020;56(4):493-497.
- Crombag N, Pizzolato D, Dierickx K. Direct access to investigational interventions outside the trial process: ethical reflections on the TOTAL-trial debate. *Ultrasound Obstet Gynecol*. 2021;57(1):177-178.
- Vergote S, Pizzolato D, Russo F, Dierickx K, Deprest J, Crombag N. The TOTAL trial dilemma: a survey among professionals on equipoise regarding fetal therapy for severe congenital diaphragmatic hernia. *Prenat Diagn*. 2021;41(2):179-189.

37. Verweij EJ, de Vries MC, Oldekamp EJ, et al. Fetoscopic myelomeningocele closure: is the scientific evidence enough to challenge the gold standard for prenatal surgery? *Prenat Diagn.* 2021;41(8):949-956.
38. Provoost V, Tilleman K, D'Angelo A, et al. Beyond the dichotomy: a tool for distinguishing between experimental, innovative and established treatment. *Hum Reprod.* 2014;29(3):413-417.
39. Grushka JR, Laberge JM, Puligandla P, Skarsgard ED, Canadian Pediatric Surgery N. Effect of hospital case volume on outcome in congenital diaphragmatic hernia: the experience of the Canadian Pediatric Surgery Network. *J Pediatr Surg.* 2009;44(5):873-876.
40. Senat MV, Bouchghoul H, Stirnemann J, et al. Prognosis of isolated congenital diaphragmatic hernia using lung-area-to-head-circumference ratio: variability across centers in a national perinatal network. *Ultrasound Obstet Gynecol.* 2018;51(2):208-213.
41. Sananes N, Regnard P, Mottet N, et al. Evaluation of a new balloon for fetal endoscopic tracheal occlusion in the nonhuman primate model. *Prenat Diagn.* 2019;39(5):403-408.
42. Basurto D, Sananes N, Bleaser T, et al. Safety and efficacy of smart tracheal occlusion device in diaphragmatic hernia lamb model. *Ultrasound Obstet Gynecol.* 2021;57(1):105-112.
43. Basurto D, Sananes N, Verbeken E, et al. New device permitting non-invasive reversal of fetal endoscopic tracheal occlusion: ex-vivo and in-vivo study. *Ultrasound Obstet Gynecol.* 2020;56(4):522-531.
44. Barnett CF, Machado RF, Sildenafil in the treatment of pulmonary hypertension. *Vasc health risk Manag.* 2006;2(4):411-422.
45. Russo FM, De Bie F, Hodges R, Flake A, Deprest J. Sildenafil for antenatal treatment of congenital diaphragmatic hernia: from bench to bedside. *Curr Pharm Des.* 2019.
46. Russo FM, Benachi A, Van Mieghem T, et al. Antenatal sildenafil administration to prevent pulmonary hypertension in congenital diaphragmatic hernia (SToP-PH): study protocol for a phase I/IIb placenta transfer and safety study. *Trials.* 2018;19(1):524.
47. Russo FM, Toelen J, Eastwood MP, et al. Transplacental sildenafil rescues lung abnormalities in the rabbit model of diaphragmatic hernia. *Thorax.* 2016;71(6):517-525.
48. Mous DS, Kool HM, Buscop-van Kempen MJ, et al. Clinically relevant timing of antenatal sildenafil treatment reduces pulmonary vascular remodeling in congenital diaphragmatic hernia. *Am J Physiol Lung Cell Mol Physiol.* 2016;311(4):L734-L742.
49. Russo FM, Hooper S, Tibboel D, et al. Antenatal therapy with sildenafil: don't throw the baby out with the bathwater. *Ultrasound Obstet Gynecol.* 2019;53(2):274-275.
50. Groom KM, Ganzevoort W, Alfirevic Z, Lim K, Papageorghiou AT. Clinicians should stop prescribing sildenafil for fetal growth restriction (FGR): comment from the STRIDER Consortium. *Ultrasound Obstetrics Gynecol.* 2018;52(3):295-296.
51. Lawrence KM, Hedrick HL, Monk HM, et al. Treprostinil improves persistent pulmonary hypertension associated with congenital diaphragmatic hernia. *J Pediatr.* 2018;200:44-49.
52. Hall K, Ogawa M, Sakarovich C, et al. Subcutaneous and intravenous treprostinil pharmacokinetics in children with pulmonary vascular disease. *J Cardiovasc Pharmacol.* 2019;73(6):383-393.
53. De Bie FR, Allegaert K, Hedrick HL, Rintoul NE, Davidson A. Treprostinil attains clinically therapeutic concentrations in neonates with pulmonary hypertension on extracorporeal membrane oxygenation support. *Pharmacotherapy.* 2020;40(10):1054-1060.
54. Antounians L, Catania VD, Montalva L, et al. Fetal lung underdevelopment is rescued by administration of amniotic fluid stem cell extracellular vesicles in rodents. *Sci Transl Med.* 2021;13(590).
55. Zani A, et al. In the Same Issue of Prenatal Diagnosis. To be completed by editor.
56. Pereira-Terra P, Deprest JA, Kholdebarin R, et al. Unique tracheal fluid MicroRNA signature predicts response to FETO in patients with congenital diaphragmatic hernia. *Ann Surg.* 2015;262(6):1130-1140.
57. Khoshgoo N, Visser R, Falk L, et al. MicroRNA-200b regulates distal airway development by maintaining epithelial integrity. *Sci Rep.* 2017;7(1):6382.
58. Khoshgoo N, Kholdebarin R, Pereira-Terra P, et al. Prenatal microRNA miR-200b therapy improves nitrofen-induced pulmonary hypoplasia associated with congenital diaphragmatic hernia. *Ann Surg.* 2019;269(5):979-987.
59. Wagner R, Jha A, Ayoub L, et al. Can circular RNAs be used as prenatal biomarkers for congenital diaphragmatic hernia? *Eur Respir J.* 2020;55(2).
60. Gregoir C, Engels AC, Gomez O, et al. Fertility, pregnancy and gynecological outcomes after fetoscopic surgery for congenital diaphragmatic hernia. *Hum Reprod.* 2016;31(9):2024-2030.
61. DeKoninck PLJ, Horn-Oudshoorn EJJ, Knol R, Crossley KJ, Reiss IKM. Knowledge gaps in the fetal to neonatal transition of infants with a congenital diaphragmatic hernia. *Frontiers in pediatrics.* 2021;9:784810.
62. Le Duc K, Mur S, Rakza T, et al. Efficacy of intact cord resuscitation compared to immediate cord clamping on cardiorespiratory adaptation at birth in infants with isolated congenital diaphragmatic hernia (CHIC). *Child.* 2021;8(5).
63. Syngelaki A, Hammami A, Bower S, Zidere V, Akolekar R, Nicolaides KH. Diagnosis of fetal non-chromosomal abnormalities on routine ultrasound examination at 11-13 weeks' gestation. *Ultrasound Obstet Gynecol.* 2019;54(4):468-476.
64. Russo FM, Cordier AG, De Catte L, Saada J, Benachi A, Deprest J. Proposal for standardized prenatal ultrasound assessment of the fetus with congenital diaphragmatic hernia by the European reference network on rare inherited and congenital anomalies (ERNICA). *Prenat Diagn.* 2018;38(9):629-637.
65. Jani JC, Cannie M, Peralta CF, Deprest JA, Nicolaides KH, Dymarkowski S. Lung volumes in fetuses with congenital diaphragmatic hernia: comparison of 3D US and MR imaging assessments. *Radiology.* 2007;244(2):575-582.
66. Ruano R, Aubry MC, Barthe B, Dumez Y, Benachi A. Three-dimensional ultrasonographic measurements of the fetal lungs for prediction of perinatal outcome in isolated congenital diaphragmatic hernia. *J Obstet Gynaecol Res.* 2009;35(6):1031-1041.
67. Cannie M, Jani J, Chaffiotte C, et al. Quantification of intrathoracic liver herniation by magnetic resonance imaging and prediction of postnatal survival in fetuses with congenital diaphragmatic hernia. *Ultrasound Obstet Gynecol.* 2008;32(5):627-632.
68. Nawapun K, Eastwood M, Sandaite I, et al. Correlation of observed-to-expected total fetal lung volume with intrathoracic organ herniation on magnetic resonance imaging in fetuses with isolated left-sided congenital diaphragmatic hernia. *Ultrasound Obstet Gynecol.* 2015;46(2):162-167.
69. Jani J, Cannie M, Sonigo P, et al. Value of prenatal magnetic resonance imaging in the prediction of postnatal outcome in fetuses with diaphragmatic hernia. *Ultrasound Obstet Gynecol.* 2008;32(6):793-799.
70. Mufti N, Aertsen M, Ebner M, et al. Cortical spectral matching and shape and volume analysis of the fetal brain pre- and post-fetal surgery for spina bifida: a retrospective study. *Neuroradiology.* 2021;63(10):1721-1734.
71. Ebner M, Wang G, Li W, et al. An automated framework for localization, segmentation and super-resolution reconstruction of fetal brain MRI. *Neuroimage.* 2020;206:116324.
72. Kotecha S, Barbato A, Bush A, et al. Congenital diaphragmatic hernia. *Eur Respir J.* 2012;39(4):820-829.
73. Done E, Debeer A, Gucciardo L, et al. Prediction of neonatal respiratory function and pulmonary hypertension in fetuses with isolated congenital diaphragmatic hernia in the fetal endoscopic tracheal occlusion era: a single-center study. *Fetal Diagn Ther.* 2015;37(1):24-32.

74. Van der Veeken L, Vergote S, Kunpalin Y, Kristensen K, Deprest J, Bruschetini M. Neurodevelopmental outcomes in children with isolated congenital diaphragmatic hernia: a systematic review and meta-analysis. *Prenat Diagn*. 2021.
75. Tracy S, Estroff J, Valim C, Friedman S, Chen C. Abnormal neuroimaging and neurodevelopmental findings in a cohort of antenatally diagnosed congenital diaphragmatic hernia survivors. *J Pediatr Surg*. 2010;45(5):958-965.
76. Danzer E, Zarnow D, Gerdes M, et al. Abnormal brain development and maturation on magnetic resonance imaging in survivors of severe congenital diaphragmatic hernia. *J Pediatr Surg*. 2012;47(3):453-461.
77. Hunt RW, Kean MJ, Stewart MJ, Inder TE. Patterns of cerebral injury in a series of infants with congenital diaphragmatic hernia utilizing magnetic resonance imaging. *J Pediatr Surg*. 2004;39(1):31-36.
78. Montalva L, Raffler G, Riccio A, Lauriti G, Zani A. Neurodevelopmental impairment in children with congenital diaphragmatic hernia: not an uncommon complication for survivors. *J Pediatr Surg*. 2019.
79. Antiel RM, Lin N, Licht DJ, et al. Growth trajectory and neurodevelopmental outcome in infants with congenital diaphragmatic hernia. *J Pediatr Surg*. 2017;52(12):1944-1948.
80. Van der Veeken L, Russo FM, Litwinska E, et al. Prenatal cerebellar growth is altered in congenital diaphragmatic hernia on ultrasound. *Prenat Diagn*. 2021.
81. Cordier AG, Russo FM, Deprest J, Benachi A. Prenatal diagnosis, imaging, and prognosis in congenital diaphragmatic hernia. *Semin Perinatol*. 2020;44(1):51163.
82. Luks FI, Deprest JA, Vandenberghe K, et al. Fetoscopy-guided fetal endoscopy in a sheep model. *J Am Coll Surg*. 1994;178(6):609-612.
83. Evrard VA, Verbeken EA, Vandenberghe K, Lerut T, Flageole H, Deprest JA. Endoscopic in utero tracheal plugging in the fetal lamb to treat congenital diaphragmatic hernia. *J Am Assoc Gynecol Laparosc*. 1996;3(4):S11.Supplement.
84. Benachi A, Dommergues M, Delezoide AL, Bourbon J, Dumez Y, Brunelle F. Tracheal obstruction in experimental diaphragmatic hernia: an endoscopic approach in the fetal lamb. *Prenat Diagn*. 1997;17(7):629-634.
85. Flageole H, Evrard VA, Piedboeuf B, Laberge JM, Lerut TE, Deprest JA. The plug-unplug sequence: an important step to achieve type II pneumocyte maturation in the fetal lamb model. *J Pediatr Surg*. 1998;33(2):299-303.
86. DeKoninck P, Gomez O, Sandaite I, et al. Right-sided congenital diaphragmatic hernia in a decade of fetal surgery. *BJOG*. 2015;122(7):940-946.
87. Reiss I, Schaible T, van den Hout L, et al. Standardized postnatal management of infants with congenital diaphragmatic hernia in Europe: the CDH EURO Consortium consensus. *Neonatology*. 2010;98(4):354-364.
88. Snoek KG, Reiss IK, Greenough A, et al. Standardized postnatal management of infants with congenital diaphragmatic hernia in Europe: the CDH EURO consortium consensus - 2015 update. *Neonatology*. 2016;110(1):66-74.
89. Engels AC, DeKoninck P, van der Merwe JL, et al. Does website-based information add any value in counseling mothers expecting a baby with severe congenital diaphragmatic hernia? *Prenat Diagn*. 2013;33(11):1027-1032.
90. Sacco A, Van der Veeken L, Bagshaw E, et al. Maternal complications following open and fetoscopic fetal surgery: a systematic review and meta-analysis. *Prenat Diagn*. 2019;39(4):251-268.