

Good clinical practice advice: Management of twin pregnancy[☆]

FIGO Working Group on Good Clinical Practice in Maternal–Fetal Medicine^{*,a}

^{*}**Correspondence:** Gian Carlo Di Renzo, Department of Obstetrics and Gynecology, University of Perugia, Santa Maria della Misericordia University Hospital, Perugia, Italy. Email: giancarlo.direnzo@unipg.it

[☆]Endorsed in March 2017 and April 2018 by the FIGO Executive Board. This advice should not be considered as standards of care or legal standards in clinical practice.

^aWorking Group members and expert contributors are listed at the end of the paper.

PREMISE

Twin pregnancy is associated with a high risk of perinatal, as well as maternal, mortality and morbidity.^{1–3} Intensive antenatal fetal surveillance is associated with a lower risk of stillbirth.⁴ The excess perinatal mortality and morbidity is higher in monochorionic than dichorionic twin pregnancy due to the placental anastomoses invariably present in the monochorionic placenta.⁵ This guideline will cover the care of both uncomplicated and complicated twin pregnancies.

ANTENATAL CARE OF TWIN PREGNANCIES

Where should antenatal care take place?

Women with a twin pregnancy should be cared for by an experienced multidisciplinary team in a specialized twin clinic.⁶ Twins that develop complications, and all monochorionic monoamniotic twins, should be referred to a tertiary center. Pregnant women with twins should be counselled about the increased risk of miscarriage, aneuploidy, structural abnormalities, anemia, preterm birth, growth disorders, venous thromboembolism, cesarean section, and postpartum haemorrhage. Hemoglobin concentration should be checked at 20–24 weeks' gestation, as well as at the usual 28 and 34 weeks. Guidance from the National Institute for Health and Care Excellence advises women with a twin pregnancy to take 75 mg of aspirin daily from 12 weeks until birth if they have an additional risk factor for pre-eclampsia.⁶

Dating of the pregnancy (determination of gestational age)

Twins conceived by in-vitro fertilization should be dated using the date of fertilization. In all other cases, the pregnancy should be dated according to the crown–rump length of the larger twin. Dating should take place when the crown–rump length is between 45 mm and 84 mm (equivalent to 11⁺⁰ to 13⁺⁶ weeks of gestation). Twin

pregnancies presenting later than 14 weeks' gestation should be dated according to the head circumference of the larger twin.⁶

Determining chorionicity and amnionicity of twin pregnancies

The chorionicity and amnionicity should be determined in the first trimester. The chorionicity is determined by examining the membrane thickness at the site of their insertion into the placenta; a T sign indicates monochorionicity, while a lambda (λ) sign is diagnostic of dichorionicity (Fig. 1).^{7–9}

Labelling of twins

During the prenatal scans, each twin should be labelled and described using as many features as possible, for example: "Twin A (female) is on the maternal left and closer to the cervix with an anterior placenta".

Timing, frequency, and content of ultrasound assessment

In uncomplicated dichorionic twin pregnancies, following the first trimester scan, subsequent scans should be performed around the following gestations: weeks 20 (the second trimester anomaly scan), 24, 28, 32, and 36 (Fig. 2).¹⁰

In uncomplicated monochorionic twin pregnancies, following the first trimester scan, further scans should be performed at least every 2 weeks from 16 weeks' gestation in order to detect twin-to-twin transfusion syndrome (Fig. 3).^{11,12}

At each ultrasound, fetal biometry (head circumference, abdominal circumference, and femur length), amniotic fluid volume, and estimated fetal weight should be assessed for both twins. If discordance in growth or fluid is noted, then umbilical artery Doppler assessment should be performed. In monochorionic diamniotic twins, assessment for twin-to-twin transfusion syndrome at each scan will include

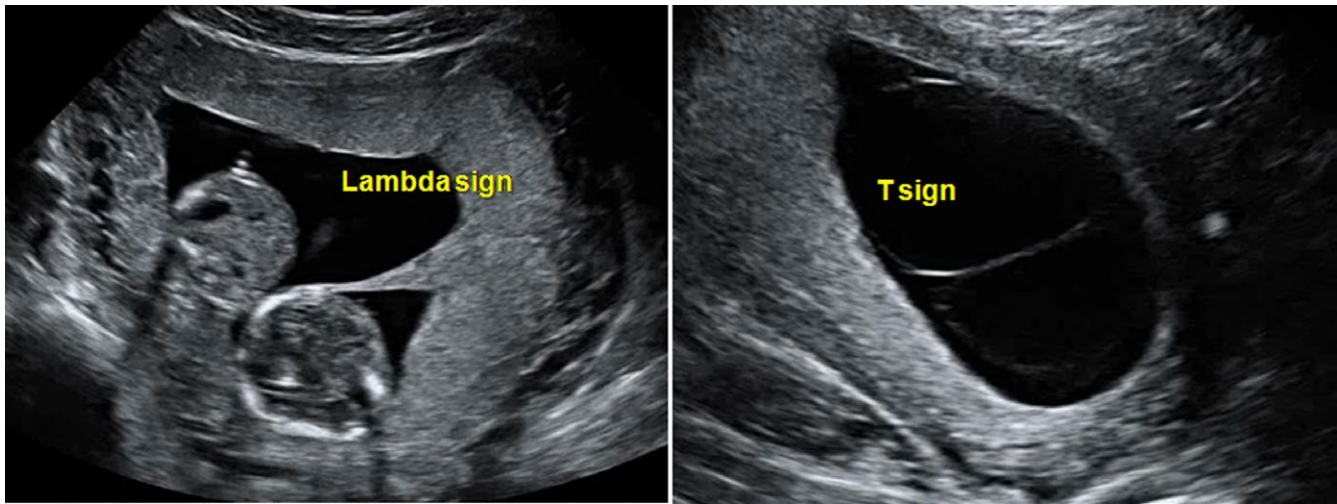


FIGURE 1 Monochorionicity and dichorionicity. A T sign indicates monozygosity, while a lambda (λ) sign is diagnostic of dichorionicity.

measurement of the deepest vertical pocket of amniotic fluid. In monozygotic twins, the middle cerebral artery peak systolic velocity should be considered from 20 weeks' gestation onwards to screen for twin anaemia polycythaemia sequence. In all twin pregnancies, the 20-week anatomy scan should include measurement of cervical length to identify women at increased risk of extreme prematurity.

Screening for and prenatal diagnosis of aneuploidy

Screening for trisomy can be offered in the first trimester (11⁺⁰ to 13⁺⁶ weeks of gestation) using the combined test or the combination of maternal age and nuchal translucency, or cell-free DNA. In the case of a vanished twin, if there is still a visible fetal pole on ultrasound scan, nuchal translucency alone (combined with maternal age) should be used as serum β -human chorionic gonadotrophin (β -hCG) and pregnancy-associated plasma protein A levels may be affected by the vanishing twin. In this case, cell-free DNA might also be less accurate, can lead to a false-positive result, and is generally not recommended.^{13,14}

Risk of pregnancy loss following invasive testing—chorionic villus sampling or amniocentesis—appears to be greater in twin than in singleton pregnancies (2% following chorionic villus sampling and 1.5%–2% following amniocentesis).¹⁵ Chorionic villus sampling is preferable in dichorionic twins because it can be performed earlier, and as a result obtained earlier, than amniocentesis. This is important because the risk of loss of the entire pregnancy associated with selective termination is significantly lower in the first trimester than in the second trimester (7% vs 14%).^{16,17}

Screening for structural abnormalities

The first trimester scan (between 11 and 13⁺⁶ weeks' gestation) should be seen as the first anatomy scan, capable of assessing the presence of any major anomalies.¹⁸ The routine second trimester anatomy scan (usually performed around 20 weeks' gestation) is more difficult and time consuming in twins than in singletons. Monozygotic twins are two to three times more likely to be affected by fetal anomaly, so

expert fetal anatomy scan, including fetal echocardiography, is essential in every case.

Twin pregnancies discordant for fetal anomaly

All twins with discordant anomaly should be referred to a tertiary referral fetal medicine center for further management. Where there is a potentially lethal abnormality of one fetus, conservative management is preferable in dichorionic twins. However, in monozygotic twins, intervention should be considered to protect the healthy co-twin from harm should the affected twin die in utero.

Fetal reduction/selective termination in twin pregnancies

Risk of miscarriage and preterm birth is thought to be lower when selective termination is performed in the first trimester.¹⁶ In the second trimester, rather than risking miscarriage or very preterm birth of the co-twin, the parents may opt for late selective termination in the third trimester if the law permits.

In dichorionic twins, selective feticide is performed by ultrasound-guided intracardiac or intrafunicular injection of potassium chloride or 1% lignocaine. In monozygotic twins, feticide is performed by cord occlusion, radiofrequency ablation, or laser ablation of the cord of the affected twin after counselling the parents of the potential risks to the surviving co-twin.^{18,19} This causes the demise of the affected twin and also isolates its circulation from that of its co-twin. Survival of the co-twin is around 80%, but there is an increased risk of adverse neurological sequelae.^{19–21}

Screening for and prevention of preterm birth

Preterm births, both spontaneous and iatrogenic, are more common in twins than in singleton pregnancies.²² Second trimester (18–24 weeks) cervical length screening by transvaginal ultrasound scan should be offered. In asymptomatic women, a cervical length threshold of 20 mm

Dichorionic Twins

Antenatal visits and ultrasound assessment

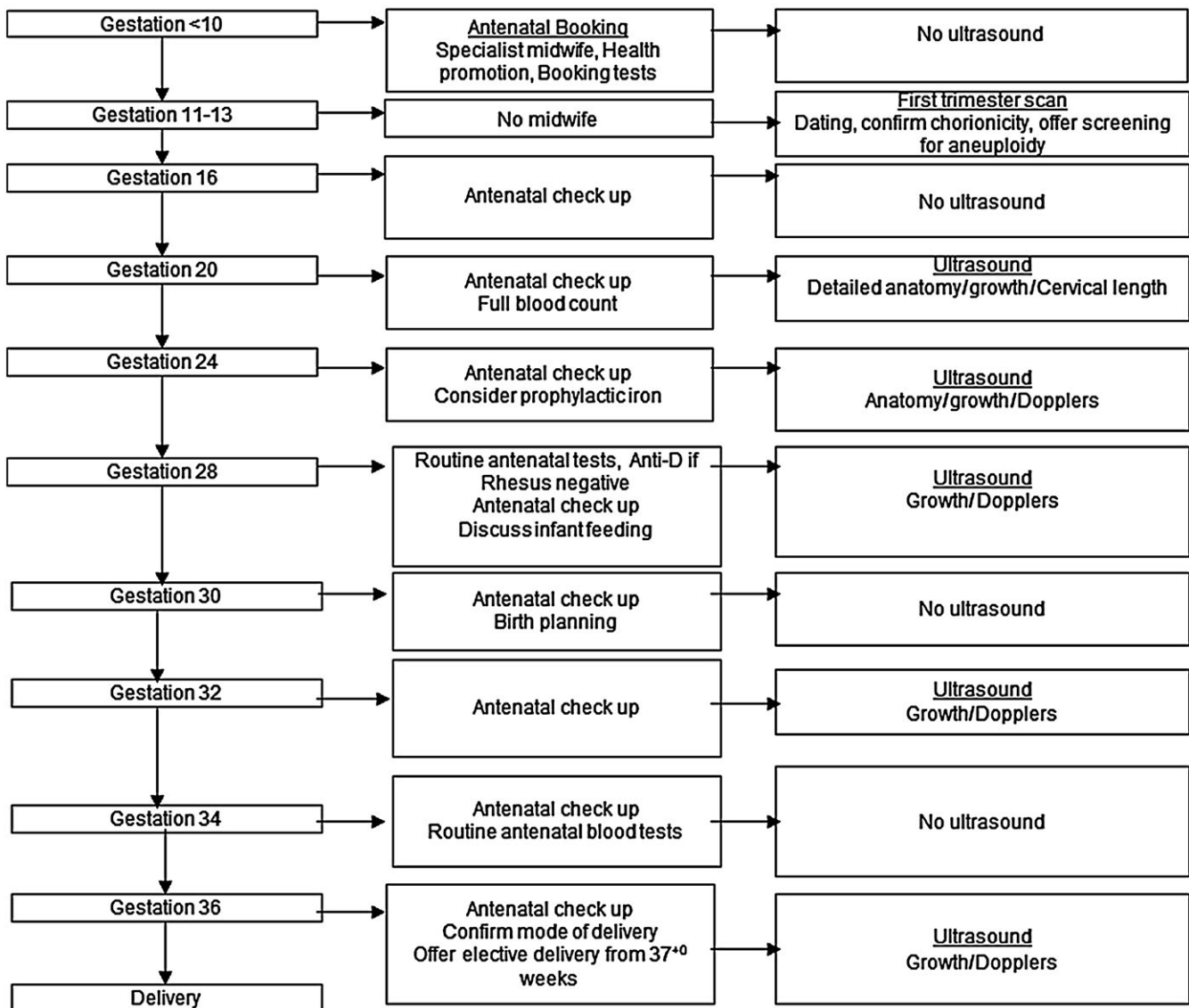


FIGURE 2 Timing, frequency, and content of ultrasound assessment in uncomplicated dichorionic twin pregnancies.

or less should be used.²³ In symptomatic women, cervical length screening has a poor predictive value for preterm birth in twins. However, even if women at increased risk of preterm birth with twins are accurately identified, there is no effective preventive strategy (this includes progesterone, bed rest, Arabin pessary, and oral tocolytics).^{6,24-29}

Steroids should be given if delivery is expected before 34 weeks, or if cesarean section is planned before 37 weeks' gestation. Repeat courses of steroids in case of threatened preterm birth should be based on individual circumstances and should no longer be routine practice.

Screening, diagnosis, and management of fetal growth restriction

The most commonly used definition of selective fetal growth restriction is when one fetus has an estimated fetal weight below

the 10th centile, with many clinicians additionally requiring an intertwin estimated fetal weight discordance of greater than 25%.³⁰ Estimated fetal weight discordance is calculated with the following formula:

$$\frac{(\text{weight of the larger twin} - \text{weight of the smaller twin}) \times 100}{\text{weight of the larger twin}}$$

When selective fetal growth restriction is diagnosed, an underlying cause should be sought.³¹ This may include a detailed anatomy scan, screen for viral infections (TORCH), and amniocentesis if chromosomal anomaly is suspected. In monochorionic twins, selective fetal growth restriction is most commonly due to unequal sharing of the placental mass and vasculature.³²

The use of twin-specific growth charts may reduce unnecessary medical intervention.³³ If the estimated fetal weight discordance in

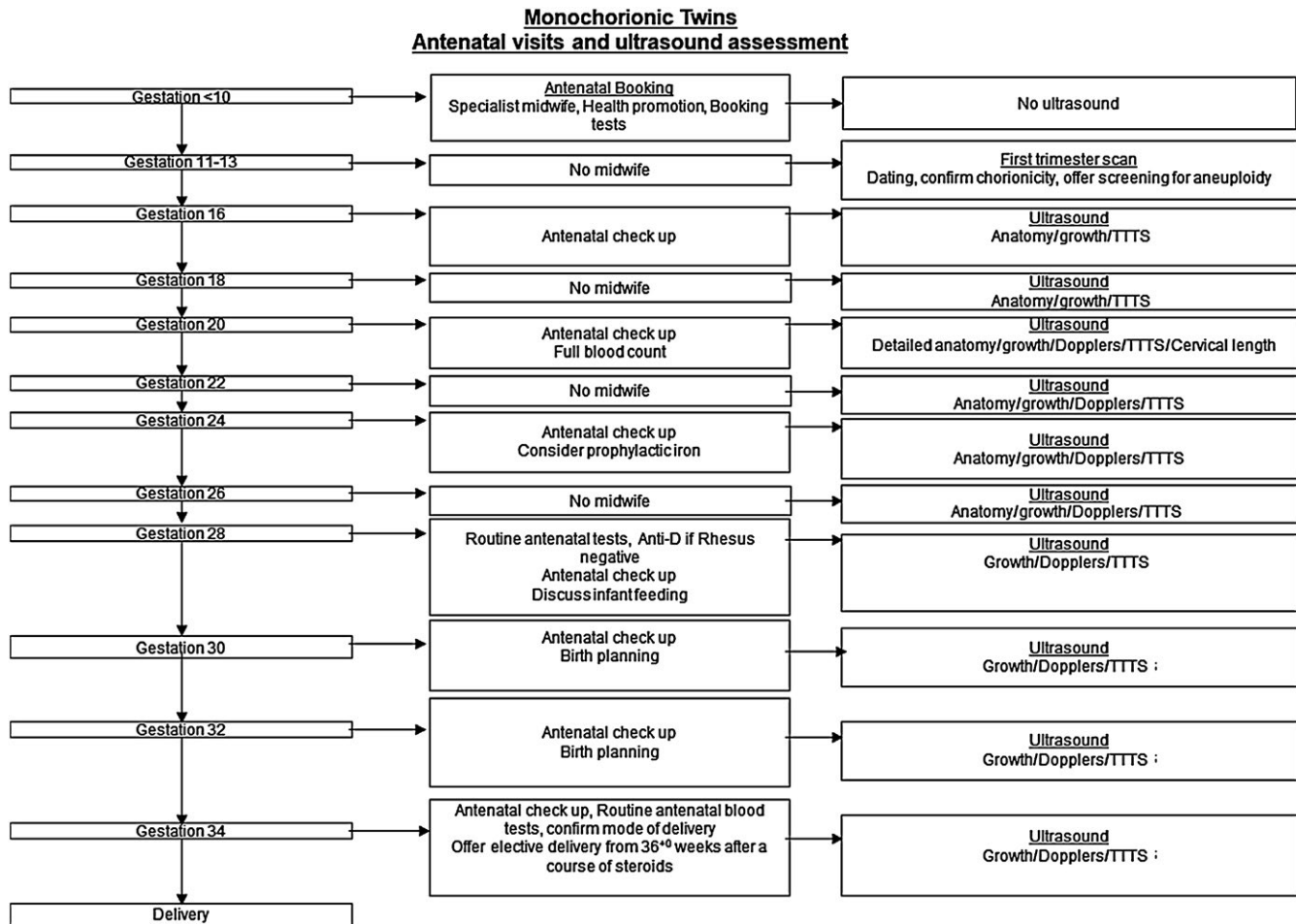


FIGURE 3 Timing, frequency, and content of ultrasound assessment in uncomplicated monochorionic twin pregnancies. Abbreviation: TTTS, twin-to-twin transfusion syndrome.

twins exceeds 25%, the woman should be referred to a tertiary level fetal medicine unit for further assessment and management, as there is an increased risk of perinatal loss.³⁴

Twin pregnancies complicated by selective fetal growth restriction should be followed up in a specialist center with serial ultrasound scans. In dichorionic twins, the timing of delivery can be decided based on the risk-benefit assessment, as in singletons. Classification of selective fetal growth restriction in monochorionic twins is complex, being divided into three types, each with different outcomes (Fig. 4).³⁵ There is little evidence to guide the management of monochorionic twins affected by selective fetal growth restriction, but options include early delivery, laser ablation, or cord occlusion of the growth restricted twin.³⁶

In monochorionic twin pregnancies complicated by selective fetal growth restriction, monitoring should be at least every 2 weeks with fetal Dopplers. If there is a real risk of demise of one twin very early (e.g. before 26 weeks' gestation), selective laser photocoagulation of the communicating vessels or selective termination should be considered in order to protect the normally grown fetus from harm should its smaller co-twin die.¹⁰

Management of multiple pregnancy complicated by single in-utero death

When death of one of a monochorionic twin pair is diagnosed, the urge to swiftly deliver the other should be resisted. This is because, if that twin is going to suffer damage, it is likely to have already occurred by the time the death of its co-twin is diagnosed. The live twin should initially be assessed for immediate compromise using cardiotocography or middle cerebral artery Doppler to assess for fetal anaemia.³⁷ Immediate delivery seems reasonable if the death occurs later in the third trimester; otherwise, immediate delivery that puts the surviving twin at risk of the complications of prematurity is not justified.

COMPLICATIONS UNIQUE TO MONOCHORIONIC TWIN PREGNANCIES

The following complications are unique to monochorionic twins: twin-to-twin transfusion syndrome, twin anaemia polycythaemia sequence, twin reversed arterial perfusion sequence, monoamniotic pregnancy and conjoined twins.

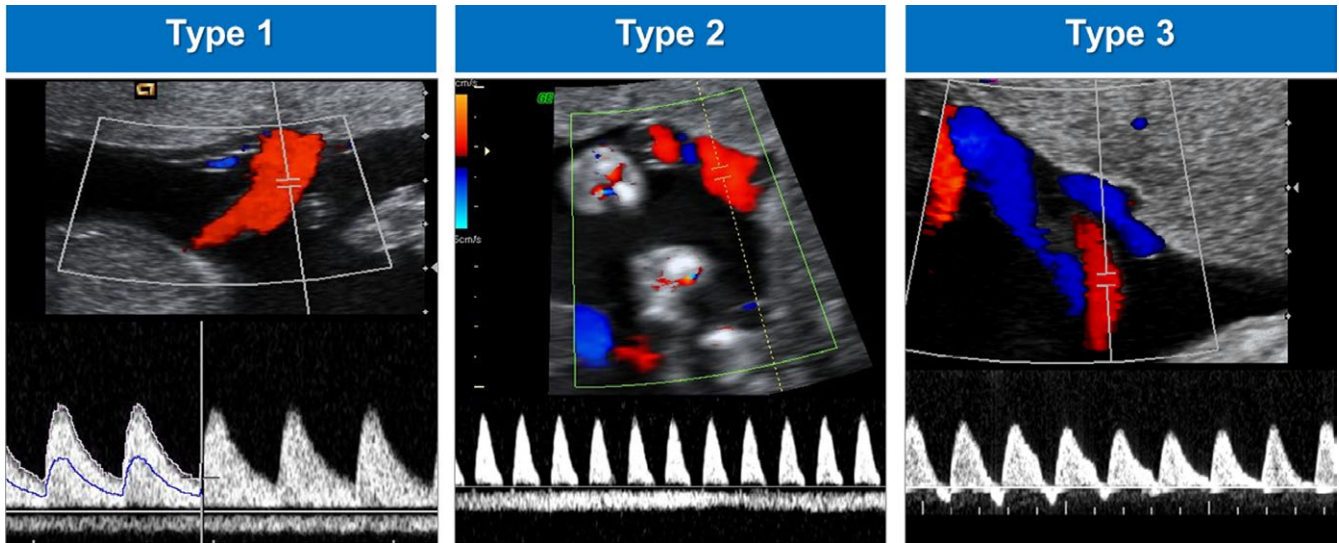


FIGURE 4 Classification of selective fetal growth restriction in monochorionic twins.³⁵

Screening, diagnosis and management of twin-to-twin transfusion syndrome

Monochorionic twins share vascular anastomoses; when there is unequal hemodynamic and amniotic fluid balance there is a risk of twin-to-twin transfusion syndrome.³⁸ Diagnosis of this syndrome is made when the donor twin has a deepest vertical pocket measurement of less than 2 cm (oligohydramnios) and the recipient has a deepest vertical pocket measurement of 8 cm or more (polyhydramnios). Size discordance between the twins is common but not essential for this diagnosis.³⁹ Twin-to-twin transfusion syndrome is staged according to the Quintero classification (Table 1)^{38,40}; an increasing Quintero stage does not necessarily correlate with increasingly poor outcome. Delivery is usually around 34 weeks' gestation, following a course of maternal steroids.⁴¹

Management of monochorionic monoamniotic twin pregnancy

Monochorionic monoamniotic twin pregnancies carry a high perinatal loss rate of up to 50% before 16 weeks' gestation. The

TABLE 1 Quintero staging system.^{38,40}

Stage	Classification
I	Polyhydramnios oligohydramnios sequence: DVP >8 cm in the recipient and <2 cm in the donor
II	Bladder in the donor twin not visible on ultrasound scan
III	Absent or reversed umbilical artery diastolic flow, reversed ductus venosus a-wave flow, pulsatile umbilical vein flow in either twin
IV	Hydrops in one or both twins
V	Death of one or both twins

Abbreviation: DVP, deepest vertical pocket.

incidence of twin-to-twin transfusion syndrome in monochorionic monoamniotic twins is 6%, with cerebral injury in a total of 5%.⁴² The timing of delivery is usually at 32–34 weeks after a course of steroids.⁴³

TIMING OF BIRTH IN UNCOMPLICATED TWIN PREGNANCY

Around 60% of twins will deliver spontaneously before 37⁺⁰ weeks of gestation. Women carrying dichorionic twins or monochorionic diamniotic twins should be offered elective delivery from 37⁺⁰ and 36 weeks' gestation, respectively.^{2,6}

MODE OF DELIVERY OF TWIN PREGNANCIES

For uncomplicated dichorionic diamniotic twins, if the leading twin is cephalic it is reasonable to aim for vaginal delivery. If twin one is non-cephalic, cesarean section is probably the safer option. In many countries, monochorionic diamniotic twins will commonly be delivered by cesarean section; however, when uncomplicated, the option of vaginal birth could be offered to the parents. There is a possible risk of acute twin-to-twin transfusion syndrome occurring during labor, although the risk of this appears to be small.^{44,45}

DELIVERY OF THE SECOND TWIN

Continuous intrapartum fetal heart monitoring is recommended. Delivery of the second twin usually occurs within 30 minutes of the first twin. Active management of the delivery of the second twin is recommended to avoid a prolonged interval. A summary of the intrapartum care is outlined in Box 1.

Box 1 Intrapartum care in twin pregnancy.

- 60% of twin pregnancies have spontaneous birth before 37⁺⁰ weeks
- All women with a twin pregnancy should be cared for in the Delivery Suite during labor
- Mode of delivery is recommended as following:
 - Vaginal delivery on labor ward if twin one is cephalic
 - Cesarean section if both twins or twin one are non-cephalic
 - Cesarean section if monochorionic monoamniotic twins

For women who aim to have vaginal delivery:

- Continuous cardiotocography of both twins throughout labor. It is recommended that twin one should be monitored using fetal scalp electrode, unless it is contraindicated. Twin two should be monitored using an external transducer
- Delivery should take place in a setting where ready recourse to operative delivery, if necessary, is available
- The anesthetist and neonatologist should be alerted at delivery
- Delivery of twin two should not be rushed if there is no cord prolapse or bleeding, and if the fetal heart rate remains normal. The interval between delivery of twin one and twin two should generally be less than 30 minutes, but may be prolonged if the fetal heart rate is normal
- Twin two may need stabilization of lie, internal podalic version, breech extraction, or immediate cesarean section
- Active management of the third stage

POSTNATAL CARE

Extra support is needed from the relevant healthcare professionals in the postnatal period. There is a three-fold increase in the risk of postnatal depression in women with multiple pregnancy compared to those with singletons. Early referral to individuals with the relevant expertise is recommended.

FIGO WORKING GROUP ON GOOD CLINICAL PRACTICE IN MATERNAL-FETAL MEDICINE (2015–2018)

Gian Carlo Di Renzo, Italy (Chair); Eduardo Fonseca, Brazil; Eduardo Gratacos, Spain; Sonia Hassan, USA; Mark Kurtser, Russia; Fergal Malone, Ireland; Shilpa Nambiar, Malaysia; Kypros Nicolaides, UK; Nancy Sierra, Mexico; Huixia Yang, China (members). Carlos Fuchtnr, Bolivia (FIGO President Elect, Ex Officio); Vincenzo Berghella, USA (Society for Maternal-Fetal Medicine); Ernesto Castelazo Morales, Mexico (FIGO Committee for Capacity Building in Education and Training); Mark Hanson, UK (FIGO Working Group on Adolescent, Preconception and Maternal Nutrition); Moshe Hod, Israel (Committee

on Pregnancy and NCD; Working Group on Hyperglycemia in Pregnancy); Yves Ville, France (International Society of Ultrasound in Obstetrics and Gynecology); Gerard Visser, Netherlands (FIGO Committee for Safe Motherhood and Newborn Health); Joe Leigh Simpson, USA (March of Dimes).

EXPERT CONTRIBUTORS

Abdallah Adra (Department of Obstetrics and Gynecology, American University of Beirut Medical Center, Lebanon); Roza Bataeva (Fetal Medicine Centre, Russian Medical Academy of Advanced Studies, Moscow, Russia); Luis Cabero Roura (Autonomous University of Barcelona, Hospital Materno-infantil Valle Hebrón, Barcelona, Spain); Ramen H. Chmait (Department of Obstetrics and Gynecology, Division of Maternal-Fetal Medicine, Keck School of Medicine, University of Southern California, USA); Yvonne Cheng (Department of Obstetrics and Gynaecology, Chinese University of Hong Kong); Irene Giardina (Centre of Perinatal and Reproductive Medicine, University of Perugia, Italy); Jon Hyett (Department of Women and Babies, Royal Prince Alfred Hospital, Australia); Asma Khalil (Fetal Medicine Unit, Department of Obstetrics and Gynaecology, St. George's University Hospitals NHS Foundation Trust, London, UK); Narendra Malhotra (Global Rainbow Healthcare, India); Pierpaolo Mastroiacovo (Alessandra Lisis International Centre on Birth Defects and Prematurity, International Clearinghouse for Birth Defects Surveillance and Research, Rome, Italy); John Morrison (Department of Obstetrics & Gynaecology, National University of Ireland); Amala Nazareth (Emirates Medical Association Ob Gyn, United Arab Emirates); Liona Chiu Yee Poon (Department of Obstetrics and Gynaecology, Chinese University of Hong Kong); Chittaranjan N. Purandare (International Federation of Gynecology and Obstetrics [FIGO], St. Elizabeth Hospital, Walkeshwar and BSES Hospital Mumbai, India); Ruben Quintero (Plantation General Hospital and Wellington Regional Medical Center, Coral Gables, Florida, USA); Waldo Sepulveda (Maternal-Fetal Diagnostic Center, Santiago, Chile); Valentina Tosto (Centre of Perinatal and Reproductive Medicine, University of Perugia, Italy).

CONFLICTS OF INTEREST

The authors have no conflicts of interest.

REFERENCES

1. Danon D, Sekar R, Hack KE, Fisk NM. Increased stillbirth in uncomplicated monochorionic twin pregnancies: A systematic review and meta-analysis. *Obstet Gynecol.* 2013;121:1318–1326.
2. Cheong-See F, Schuit E, Arroyo-Manzano D, et al.; Global Obstetrics Network (GONet) Collaboration. Prospective risk of stillbirth and neonatal complications in twin pregnancies: Systematic review and meta-analysis. *BMJ.* 2016;354:i4353.
3. Lee YM, Wylie BJ, Simpson LL, D'Alton ME. Twin chorionicity and the risk of stillbirth. *Obstet Gynecol.* 2008;111:301–308.
4. Burgess JL, Unal ER, Nietert PJ, Newman RB. Risk of late-preterm stillbirth and neonatal morbidity for monochorionic and dichorionic twins. *Am J Obstet Gynecol.* 2014;210(578):e1–e9.

5. Sebire NJ, Snijders RJ, Hughes K, Sepulveda W, Nicolaides KH. The hidden mortality of monochorionic twin pregnancies. *Br J Obstet Gynaecol.* 1997;104:1203–1207.
6. National Collaborating Center for Women's and Children's Health (UK). *Multiple Pregnancy: The Management of Twin and Triplet Pregnancies in the Antenatal Period.* London: RCOG Press; 2011.
7. Sepulveda W, Sebire NJ, Hughes K, Odibo A, Nicolaides KH. The lambda sign at 10–14 weeks of gestation as a predictor of chorionicity in twin pregnancies. *Ultrasound Obstet Gynecol.* 1996;7:421–423.
8. Sepulveda W, Sebire NJ, Hughes K, Kalogeropoulos A, Nicolaides KH. Evolution of the lambda or twin-chorionic peak sign in dichorionic twin pregnancies. *Obstet Gynecol.* 1997;89:439–441.
9. Monteagudo A, Timor-Tritsch IE. Second- and third-trimester ultrasound evaluation of chorionicity and amnionicity in twin pregnancy. A simple algorithm. *J Reprod Med.* 2000;45:476–480.
10. Khalil A, Rodgers M, Baschat A, et al. ISUOG Practice Guidelines: Role of ultrasound in twin pregnancy. *Ultrasound Obstet Gynecol.* 2016;47:247–263.
11. Sueters M, Middeldorp JM, Lopriore E, Oepkes D, Kanhai HH, Vandenbussche FP. Timely diagnosis of twin-to-twin transfusion syndrome in monochorionic twin pregnancies by biweekly sonography combined with patient instruction to report onset of symptoms. *Ultrasound Obstet Gynecol.* 2006;28:659–664.
12. de Villiers SF, Slaghekke F, Middeldorp JM, Walther FJ, Oepkes D, Lopriore E. Placental characteristics in monochorionic twins with spontaneous versus post-laser twin anemia-polycythemia sequence. *Placenta.* 2013;34:456–459.
13. Prats P, Rodríguez I, Comas C, Puerto B. Systematic review of screening for trisomy 21 in twin pregnancies in first trimester combining nuchal translucency and biochemical markers: A meta-analysis. *Prenat Diagn.* 2014;34:1077–1083.
14. Gil MM, Accurti V, Santacruz B, Plana MN, Nicolaides KH. Analysis of cell-free DNA in maternal blood in screening for aneuploidies: Updated meta-analysis. *Ultrasound Obstet Gynecol.* 2017;50:302–314.
15. Gallot D, Vélémir L, Delabaere A, et al. Which invasive diagnostic procedure should we use for twin pregnancies: Chorionic villous sampling or amniocentesis? *J Gynecol Obstet Biol Reprod.* 2009;38:S39–S44.
16. Evans MI, Goldberg JD, Horenstein J, et al. Selective termination for structural, chromosomal, and Mendelian anomalies: International experience. *Am J Obstet Gynecol.* 1999;181:893–897.
17. Machin G. Nonidentical monozygotic twins, intermediate twin types, zygosity testing, and the nonrandom nature of monozygotic twinning: A review. *Am J Med Genet C Semin Med Genet.* 2009;151C:110–127.
18. Rossi AC, D'Addario V. Umbilical cord occlusion for selective fetocide in complicated monochorionic twins: A systematic review of literature. *Am J Obstet Gynecol.* 2009;200:123–129.
19. Roman A, Papanna R, Johnson A, et al. Selective reduction in complicated monochorionic pregnancies: Radiofrequency ablation vs. bipolar cord coagulation. *Ultrasound Obstet Gynecol.* 2010;36:37–41.
20. Bebbington MW, Danzer E, Moldenhauer J, Khalek N, Johnson MP. Radiofrequency ablation vs bipolar umbilical cord coagulation in the management of complicated monochorionic pregnancies. *Ultrasound Obstet Gynecol.* 2012;40:319–324.
21. van den Bos EM, van Klink JM, Middeldorp JM, Klumper FJ, Oepkes D, Lopriore E. Perinatal outcome after selective fetocide in monochorionic twin pregnancies. *Ultrasound Obstet Gynecol.* 2013;41:653–658.
22. Martin JA, Hamilton BE, Sutton PD, et al. Births: Final data for 2006. *Natl Vital Stat Rep.* 2009;57:1–102.
23. Conde-Agudelo A, Romero R, Hassan SS, Yeo L. Transvaginal sonographic cervical length for the prediction of spontaneous preterm birth in twin pregnancies: A systematic review and meta-analysis. *Am J Obstet Gynecol.* 2010;203(128):e1–e12.
24. Romero R, Nicolaides K, Conde-Agudelo A, et al. Vaginal progesterone in women with an asymptomatic sonographic short cervix in the midtrimester decreases preterm delivery and neonatal morbidity: A systematic review and metaanalysis of individual patient data. *Am J Obstet Gynecol.* 2012;206(124):e1–e19.
25. Crowther CA. Hospitalisation and bed rest for multiple pregnancy. *Cochrane Database Syst Rev* 2010;(7):CD000110.
26. Yamasmit W, Chaithongwongwatthana S, Tolosa JE, Limpongsanurak S, Pereira L, Lumbiganon P. Prophylactic oral betamimetics for reducing preterm birth in women with a twin pregnancy. *Cochrane Database Syst Rev* 2015;(12):CD004733.
27. Norman JE, Mackenzie F, Owen P, et al. Progesterone for the prevention of preterm birth in twin pregnancy (STOPPIT): A randomised, double-blind, placebo-controlled study and meta-analysis. *Lancet.* 2009;373:2034–2040.
28. Rafael TJ, Berghella V, Alfirevic Z. Cervical stitch (cerclage) for preventing preterm birth in multiple pregnancy. *Cochrane Database Syst Rev* 2014;(9):CD009166.
29. Romero R, Conde-Agudelo A, El-Refaie W, et al. Vaginal progesterone decreases preterm birth and neonatal morbidity and mortality in women with a twin gestation and a short cervix: An updated meta-analysis of individual patient data. *Ultrasound Obstet Gynecol.* 2017;49:303–314.
30. Khalil A, Beune I, Hecher K, et al. Consensus definition and essential reporting parameters of selective fetal growth restriction in twin pregnancy: A Delphi procedure. *Ultrasound Obstet Gynecol.* 2018. <https://doi.org/10.1002/uog.19013>.
31. Sueters M, Oepkes D. Diagnosis of twin-twin-to-twin transfusion syndrome, selective fetal growth restriction, twin anemia-polycythemia sequence, and twin reversed arterial perfusion sequence. Best practice and research. *Clin Obstet Gynecol* 2014;28:215–226.
32. Lewi L, Gucciardo L, Huber A, et al. Clinical outcome and placental characteristics of monochorionic diamniotic twin pairs with early- and late-onset discordant growth. *Am J Obstet Gynecol.* 2008;199(511):e1–e7.
33. Kalafat E, Sebghati M, Thilaganathan B, Khalil A; Southwest Thames Obstetric Research Collaborative (STORK). Predictive accuracy of the Southwest Thames Obstetric Research Collaborative (STORK) chorionicity-specific twin growth charts for stillbirth: A validation study. *Ultrasound Obstet Gynecol* 2018. <https://doi.org/10.1002/uog.19069>.
34. D'Antonio F, Khalil A, Dias T, Thilaganathan B; Southwest Thames Obstetric Research Collaborative (STORK). Weight discordance and perinatal mortality in twins: Analysis of the Southwest Thames Obstetric Research Collaborative (STORK) multiple pregnancy cohort. *Ultrasound Obstet Gynecol* 2013;41:643–648.
35. Gratacós E, Lewi L, Muñoz B, et al. A classification system for selective intrauterine growth restriction in monochorionic pregnancies according to umbilical artery Doppler flow in the smaller twin. *Ultrasound Obstet Gynecol.* 2007;30:28–34.
36. Chalouhi GE, Marangoni MA, Quibel T, et al. Active management of selective intrauterine growth restriction with abnormal Doppler in monochorionic diamniotic twin pregnancies diagnosed in the second trimester of pregnancy. *Prenat Diagn.* 2013;33:109–115.
37. Senat MV, Couderc S, Bernard J, Ville Y. The value of middle cerebral artery peak systolic velocity in the diagnosis of fetal anemia after intrauterine death of one monochorionic twin. *Am J Obstet Gynecol.* 2003;189:1320–1324.
38. Quintero RA, Morales WJ, Allen MH, Bornick PW, Johnson PK, Kruger M. Staging of twin-twin transfusion syndrome. *J Perinatol.* 1999;19:550–555.
39. Khalil A. Modified diagnostic criteria for twin-to-twin transfusion syndrome prior to 18 weeks' gestation: Time to change? *Ultrasound Obstet Gynecol.* 2017;49:804–805.
40. Quintero RAM, Dickinson JE, Morales WJ, et al. Stage-based treatment of twin-twin transfusion syndrome. *Am J Obstet Gynecol.* 2003;188:1333–1340.

41. Vanderbilt DL, Schrager SM, Llanes A, Hamilton A, Seri I, Chmait RH. Predictors of two-year cognitive performance after laser surgery for twin-twin transfusion syndrome. *Am J Obstet Gynecol.* 2014;211(388):e1-e7.
42. Benirschke K, Kim CK. Multiple pregnancy. 1. *N Engl J Med* 1973;288:1276-1284.
43. Hack KE, Derks JB, Schaap AH, et al. Perinatal outcome of monoamniotic twin pregnancies. *Obstet Gynecol.* 2009;113:353-360.
44. Agarwal U, Dahiya P, Khosla A. Vaginal birth of conjoined thoracopagus: A rare event. *Arch Gynecol Obstet.* 2003;269:66-67.
45. Barrett JF, Hannah ME, Hutton EK, et al.; Twin Birth Study Collaborative Group. A randomized trial of planned cesarean or vaginal delivery for twin pregnancy. *N Engl J Med* 2013;369:1295-1305.