

# Fetal intra-abdominal bowel dilation in prediction of complex gastroschisis

W. S. ANDRADE<sup>1,2</sup>, M. L. BRIZOT<sup>2</sup>, R. P. V. FRANCISCO<sup>2</sup>, A. C. TANNURI<sup>3</sup>, A. SYNGELAKI<sup>1</sup> , R. AKOLEKAR<sup>4</sup>  and K. H. NICOLAIDES<sup>1</sup>

<sup>1</sup>Fetal Medicine Research Institute, King's College Hospital, London, UK; <sup>2</sup>Department of Obstetrics and Gynecology, São Paulo University Medical School, São Paulo, Brazil; <sup>3</sup>Division of Pediatric Surgery, Department of Pediatrics, São Paulo University Medical School, São Paulo, Brazil; <sup>4</sup>Department of Fetal Medicine, Medway Maritime Hospital, Gillingham, UK

**KEYWORDS:** bowel atresia; bowel dilatation; bowel necrosis; bowel perforation; bowel stenosis; fetal gastroschisis

## ABSTRACT

**Objective** To investigate intra-abdominal bowel dilation (IABD) in the prediction of complex gastroschisis.

**Methods** This was a retrospective study of 174 singleton pregnancies with isolated fetal gastroschisis, resulting in live birth and with available ultrasound images from visits at both 20–22 and 30–32 weeks' gestation. IABD was measured as the greatest transverse diameter of the most dilated intra-abdominal bowel segment, by an operator blinded to postnatal outcome. The distribution of IABD measurements in those with complex and those with simple gastroschisis was determined and the best cut-off value to predict complex gastroschisis was selected using receiver–operating characteristics (ROC) curves. The area under the ROC curve (AUC), detection rate (DR), false-positive rate (FPR), positive predictive value (PPV) and negative predictive value (NPV) were determined.

**Results** The study population included 39 (22.4%) cases of complex and 135 (77.6%) cases of simple gastroschisis. In the prediction of complex gastroschisis, the AUC at 20–22 weeks' gestation was 0.742 (95% CI, 0.628–0.856) and the respective value for 30–32 weeks was 0.820 (95% CI, 0.729–0.910). At the IABD cut-off of 7 mm at 20–22 weeks, DR, FPR, PPV and NPV for complex gastroschisis were 61.5%, 6.7%, 72.7% and 89.4%, respectively, and at IABD cut-off of 14 mm at 30–32 weeks, the respective values were 64.9%, 5.9%, 75.0% and 90.7%.

**Conclusion** Measurement of IABD at 20–22 or at 30–32 weeks' gestation is useful in the prediction of complex gastroschisis. Copyright © 2019 ISUOG. Published by John Wiley & Sons Ltd.

## INTRODUCTION

Gastroschisis is the most common abdominal wall defect and its incidence varies between 2 and 5 per 10 000 live births, depending on the investigated population<sup>1</sup>. The prognosis is generally good, but in up to 10% of cases, neonatal or infant death occurs, mainly as a result of complex gastroschisis, which involves bowel atresia, stenosis, necrosis or perforation at birth, and in 30% of cases leads to short-bowel syndrome<sup>2,3</sup>. Mortality in complex gastroschisis is 3.6 times higher than in simple gastroschisis<sup>3</sup>.

Several sonographic features have been proposed as prenatal predictors of complex gastroschisis, including intra- and extra-abdominal bowel dilation, bowel-wall thickness and polyhydramnios, but the only one that has been shown consistently to be beneficial is intra-abdominal bowel dilation (IABD)<sup>4–9</sup>. This was also found to be the case in a meta-analysis on prenatal prediction of adverse outcome in cases of gastroschisis; however, in this meta-analysis, there was large variation between the studies in gestational age at evaluation (19–37 weeks) and in the cut-offs used to define bowel dilation (6–19 mm)<sup>10</sup>. Consequently, the detection rates of complex gastroschisis using IABD varied between 50% and 100%.

The objective of this study was to define cut-offs of IABD for the prediction of complex gastroschisis in the second and early-third trimesters of pregnancy.

## METHODS

### Study design and participants

This was a retrospective cohort study that included patients with isolated fetal gastroschisis who underwent antenatal ultrasound and delivered at one of three referral centers (King's College Hospital, London, UK;

Correspondence to: Prof. K. H. Nicolaides, Fetal Medicine Research Institute, King's College Hospital, 16–20 Windsor Walk, Denmark Hill, London SE5 8BB, UK (e-mail: kypros@fetalmedicine.com)

Accepted: 3 June 2019

Medway Maritime Hospital, Gillingham, UK; Hospital das Clínicas, São Paulo University Medical School, São Paulo, Brazil) between January 2005 and December 2018. Gestational age was determined by the measurement of fetal crown–rump length at 11–13 weeks or fetal head circumference at 19–24 weeks<sup>11,12</sup>.

### Inclusion criteria

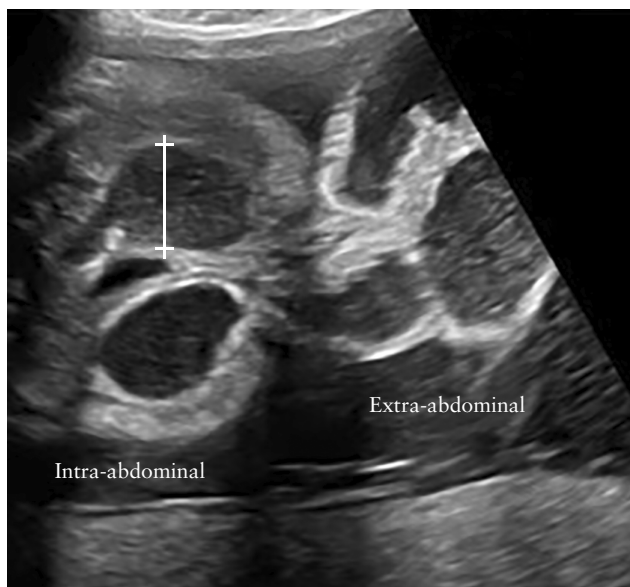A database search was performed to identify all singleton pregnancies with isolated fetal gastroschisis resulting in live birth and with available digital ultrasound images allowing measurement of IABD at both 20–22 and 30–32 weeks' gestation. IABD was measured as the greatest transverse diameter (inner-to-inner wall) of the most dilated intra-abdominal bowel segment (Figure 1) by an operator (W.S.A.) blinded to postnatal outcome.

### Patient characteristics

Patient characteristics recorded included maternal age and weight, racial origin, method of conception (spontaneous or assisted by use of ovulation induction drugs or *in-vitro* fertilization), cigarette smoking during pregnancy, medical history of chronic hypertension or diabetes mellitus, obstetric history (nulliparous if no previous pregnancy at  $\geq 24$  weeks or parous) and development of gestational hypertension or gestational diabetes mellitus in the current pregnancy.

### Outcome measures

Data on pregnancy outcome were collected from the hospital records of the mother and baby. The primary outcome for the study was complex gastroschisis, defined as the presence of intestinal atresia, stenosis,



**Figure 1** Ultrasound image of cross section of abdomen in fetus with gastroschisis, demonstrating intra- and extra-abdominal bowel dilation. Calipers and line indicate diameter of dilated intra-abdominal bowel segment.

perforation, necrosis or volvulus. Secondary outcomes included preterm birth, small-for-gestational-age neonate with birth weight  $< 10^{\text{th}}$  percentile according to The Fetal Medicine Foundation fetal and neonatal population weight charts<sup>13</sup>, postnatal death before discharge from the neonatal unit, length of neonatal hospitalization, duration of parenteral nutrition and short-bowel syndrome.

### Statistical analysis

Data were expressed as median and interquartile range for continuous variables and  $n$  (%) for categorical variables. Mann–Whitney  $U$ -test and  $\chi^2$  test or Fisher's exact test were used for comparison of continuous and categorical data, respectively, between outcome groups. Significance was assumed at 5%.

The distribution of IABD measurements in those with complex and those with simple gastroschisis at 20–22 and at 30–32 weeks' gestation was determined and the best cut-off value to predict complex gastroschisis was selected using receiver–operating characteristics (ROC) curves. The area under the ROC curve (AUC), detection rate (DR), false-positive rate (FPR), positive predictive value (PPV) and negative predictive value (NPV) were determined.

The statistical package SPSS version 24.0 (IBM Corp., Armonk, NY, USA) was used for data analyses.

## RESULTS

### Study population

The database search identified 174 patients who fulfilled the entry criteria of isolated fetal gastroschisis resulting in live birth and with available data and images of IABD at 20–22 and at 30–32 weeks' gestation. These included 39 (22.4%) cases of complex and 135 (77.6%) of simple gastroschisis. The demographic and pregnancy characteristics of the two groups are compared in Table 1. In the cases of complex gastroschisis, compared to those with simple gastroschisis, there was higher median IABD at 20–22 and at 30–32 weeks' gestation, higher incidence of spontaneous preterm birth, postnatal death, short-bowel syndrome and dependence on parenteral nutrition, and longer duration of neonatal hospitalization and parenteral nutrition.

### Intra-abdominal bowel dilation

The distribution of IABD in those with complex and those with simple gastroschisis at 20–22 and 30–32 weeks' gestation is shown in Figure 2 and the ROC curves in Figure 3. In the prediction of complex gastroschisis, the AUC at 20–22 weeks' gestation was 0.742 (95% CI, 0.628–0.856) and the respective value for 30–32 weeks was 0.820 (95% CI, 0.729–0.910). At the IABD cut-off of 7 mm at 20–22 weeks, the DR, FPR, PPV and NPV for complex gastroschisis were 61.5%, 6.7%, 72.7% and 89.4%, respectively, and at IABD cut-off of 14 mm at 30–32 weeks, the respective values were 64.9%, 5.9%, 75.0% and 90.7%.

**Table 1** Maternal, pregnancy and neonatal characteristics of study population of 174 pregnancies with fetal gastroschisis, according to whether defect was complex or simple

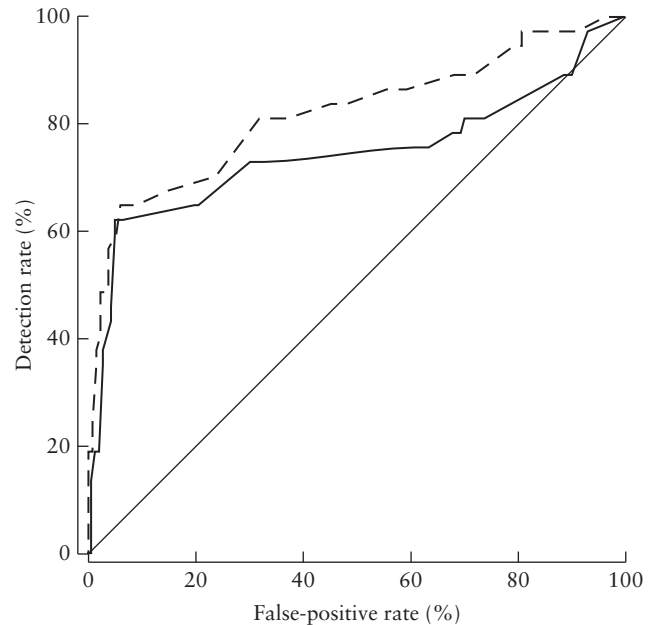
| Characteristic                           | Complex (n = 39)  | Simple (n = 135) |
|--|-------------------|------------------|
| Maternal age (years)                     | 20 (19.0–24.0)    | 21.0 (19.0–25.0) |
| Maternal weight (kg)                     | 63.0 (55.0–72.0)  | 62.0 (56.0–71.0) |
| White racial origin                      | 30 (76.9)         | 97 (71.9)        |
| Nulliparous                              | 31 (79.5)         | 96 (71.1)        |
| Smoker                                   | 9 (23.1)          | 28 (20.7)        |
| Spontaneous conception                   | 39 (100)          | 135 (100)        |
| Medical condition                        |                   |                  |
| Chronic hypertension                     | 1 (2.6)           | 1 (0.7)          |
| DM Type 1 or 2                           | 0 (0)             | 0 (0)            |
| Intra-abdominal bowel dilation (mm)      |                   |                  |
| 20–22 weeks                              | 7 (5–9)*          | 4 (3–5)          |
| 30–32 weeks                              | 16 (10–19)*       | 8 (6–10)         |
| Pregnancy complication                   |                   |                  |
| GH                                       | 1 (2.6)           | 2 (1.5)          |
| Gestational DM                           | 2 (5.1)           | 1 (0.7)          |
| GA at delivery (weeks)                   | 35.7 (34.8–37.0)* | 36.6 (35.3–37.3) |
| Delivery < 37 weeks                      | 28 (71.8)*        | 74 (54.8)        |
| Spontaneous                              | 21 (53.8)*        | 43 (31.9)        |
| Iatrogenic                               | 7 (17.9)          | 31 (23.0)        |
| Birth weight (g)                         | 2240 (2041–2678)  | 2380 (1955–2700) |
| Birth weight < 10 <sup>th</sup> p        | 21 (53.8)         | 79 (58.5)        |
| Postnatal death                          | 7 (17.9)*         | 5 (3.7)          |
| Complications in survivors               |                   |                  |
| Neonatal hospitalization (days)          | 105 (64–213)*     | 34 (28–47)       |
| Duration of parenteral nutrition (days)† | 71 (38–104)*      | 27 (22–38)       |
| Parenteral nutrition-dependent           | 7/32 (21.9)*      | 0 (0)            |
| Short-bowel syndrome                     | 12/32 (37.5)*     | 0 (0)            |

Data are given as median (interquartile range), *n* (%) or *n/N* (%). \**P* < 0.05. †Excluding those that remained parenteral nutrition-dependent. DM, diabetes mellitus; GA, gestational age; GH, gestational hypertension; p, percentile.

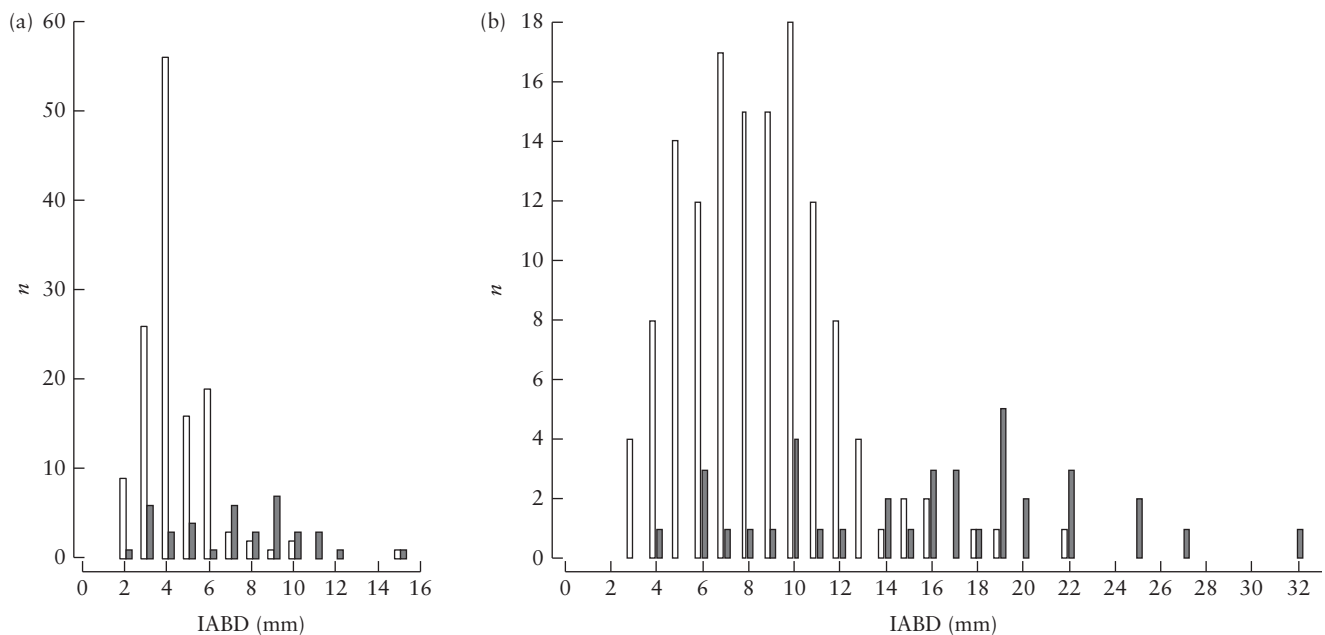
## DISCUSSION

### Main findings

The findings of this study demonstrate that, first, about 20% of cases of isolated gastroschisis are complex, second, in complex, compared to simple, gastroschisis, IABD both at 20–22 and at 30–32 weeks' gestation is higher, third, the PPV and NPV for complex gastroschisis of both IABD  $\geq 7$  mm at 20–22 weeks and IABD



**Figure 3** Receiver–operating characteristics curves for prediction of complex gastroschisis by intra-abdominal bowel dilation measurement at 20–22 (—) and 30–32 (---) weeks' gestation; areas under the curves are 0.742 (95% CI, 0.628–0.856) and 0.820 (95% CI, 0.729–0.910), respectively.



**Figure 2** Distribution of intra-abdominal bowel dilation (IABD) measurements at 20–22 (a) and 30–32 (b) weeks' gestation in fetuses with simple (□) and those with complex (■) gastroschisis.

$\geq 14$  mm at 30–32 weeks are about 75% and 90%, respectively, fourth, complex gastroschisis is associated with an increased risk of spontaneous preterm birth, postnatal death, short-bowel syndrome and dependence on parenteral nutrition and longer duration of neonatal hospitalization and of parenteral nutrition, and, fifth, both complex and simple gastroschisis are associated with a very high incidence of small-for-gestational-age neonates.

### Comparison with results of previous studies

Our finding that prenatal IABD provides useful prediction of complex gastroschisis is consistent with the findings of a meta-analysis examining the performance of various prenatal sonographic findings for prediction of adverse outcome in cases of gastroschisis; however, in this meta-analysis, there was large heterogeneity in the included studies in terms of study design, gestational age at evaluation and cut-offs used to define IABD, making it impossible to report on the predictive performance of different cut-offs of IABD<sup>10</sup>.

Our findings are also consistent with those of three recent studies which found that IABD during the third trimester is associated with increased risk for complex gastroschisis<sup>7,8,14</sup>. One study of 94 cases used the cut-off of 14 mm to predict bowel atresia and reported DR of 57%, FPR of 25%, PPV of 29% and NPV of 91%<sup>14</sup>. Another two studies of 117<sup>7</sup> and 200<sup>8</sup> cases, used the cut-off of 19 mm to predict complex gastroschisis; the DR, FPR, PPV and NPV in the first study were 50%, 9%, 47% and 92%, respectively<sup>7</sup>, and the corresponding values in the second study were 64%, 12%, 82% and 75%<sup>8</sup>. Variations between the studies may, at least in part, be the consequence of differences in the gestational age at measurement of IABD.

### Implications for clinical practice

The findings of this study could provide the basis for improved counseling of parents in pregnancies with isolated fetal gastroschisis. On the assumption that the cut-offs of IABD that we identified are confirmed by future multicenter studies, parents can be counseled that, if IABD is low, the risk of adverse outcome is substantially reduced (NPV of about 90%) and, if the measurement is high, the risk of adverse outcome is substantially increased (PPV of about 75%).

At 20–22 weeks' gestation, the results of IABD measurement may influence the parental decision in favor of or against pregnancy termination in countries in which such practice is legal. At 30–32 weeks' gestation, the results of IABD measurement may, first, help prepare the parents for the anticipated pregnancy outcome, second, help their obstetricians to select the appropriate center for delivery because those at high-risk of complex gastroschisis should be delivered at a unit with very good pediatric surgery and neonatal facilities as, in most cases, bowel resection is required and there is a higher incidence of spontaneous premature birth, neonatal complications

and short-bowel syndrome<sup>15,16</sup>, and, third, help stratify pregnancies for future studies that would investigate whether antenatal interventions, such as iatrogenic early delivery, could improve postnatal outcome.

### Strengths and limitations

Strengths of our study include, first, the relatively large cohort of cases of gastroschisis, second, selection of complex gastroschisis as the outcome measure, which is widely accepted as an indicator of adverse perinatal and long-term outcome, third, measurement of IABD on stored images by one operator blinded to neonatal outcome, ensuring uniformity of technique, fourth, measurement of IABD at 20–22 weeks' gestation, which is the gestational age at which routine ultrasound examination is performed, thereby allowing parental counseling concerning prognosis, and at 30–32 weeks, when decisions are made concerning the place and timing of delivery, and, fifth, use of ROC curves to select the appropriate cut-offs for best predictive performance of the test.

Limitations include, first, the retrospective nature of the study which was conducted at three centers that did not follow the same protocol of prenatal and postnatal care and, second, that this was not a consecutive series of all cases of gastroschisis examined in our fetal medicine units, but rather only those resulting in live birth and with available images from visits at both 20–22 and 30–32 weeks' gestation. However, these limitations do not invalidate the conclusion that IABD predicts adverse outcome.

### Conclusions

Measurement of IABD at 20–22 or at 30–32 weeks' gestation is useful in the prediction of complex gastroschisis. Multicenter prospective studies are needed to validate our findings and determine whether stratification of management based on measurements of IABD can improve outcome.

### ACKNOWLEDGMENT

This study was supported by a grant from The Fetal Medicine Foundation (Charity No: 1037116).

### REFERENCES

- Castilla EE, Mastroiacovo P, Orioli IM. Gastroschisis: international epidemiology and public health perspectives. *Am J Med Genet C Semin in Med Genet* 2008; **148C**: 162–179.
- Molik KA, Gingalewski CA, West KW, Rescorla FJ, Scherer LR, Engum SA, Grosfeld JL. Gastroschisis: a plea for risk categorization. *J Pediatr Surg* 2001; **36**: 51–55.
- Lap CC, Brizot ML, Pistorius LR, Kramer WL, Teeuwen IB, Eijkemans MJ, Brouwers HA, Pajkrt E, van Kaam AH, van Scheltema PN, Eggink AJ, van Heijst AF, Haak MC, van Weissenbruch MM, Sleetboom C, Willekes C, van der Hoeven MA, van Heurn EL, Bilardo CM, Dijk PH, van Baren R, Francisco RP, Tannuri AC, Visser GH, Manten GT. Outcome of isolated gastroschisis; an international study, systematic review and meta-analysis. *Early Hum Dev* 2016; **103**: 209–218.
- Contro E, Fratelli N, Okoye B, Papageorghiou A, Thilaganathan B, Bhida A. Prenatal ultrasound in the prediction of bowel obstruction in infants with gastroschisis. *Ultrasound Obstet Gynecol* 2010; **35**: 702–707.
- Ghionzoli M, James CP, David AL, Shah D, Tan AW, Iskaros J, Drake DP, Curry JI, Kiely EM, Cross K, Eaton S, De Coppi P, Pierrro A. Gastroschisis with intestinal

- atresia-predictive value of antenatal diagnosis and outcome of postnatal treatment. *J Pediatr Surg* 2012; **47**: 322–328.
6. Kuleva M, Khen-Dunlop N, Dumez Y, Ville Y, Salomon LJ. Is complex gastroschisis predictable by prenatal ultrasound? *BJOG* 2012; **119**: 102–109.
  7. Martillotti G, Boucoiran I, Damphousse A, Grignon A, Dubé E, Moussa A, Bouchard S, Morin L. Predicting perinatal outcome from prenatal ultrasound characteristics in pregnancies complicated by gastroschisis. *Fetal Diagn Ther* 2016; **39**: 279–286.
  8. Geslin D, Clermidi P, Gatibelza ME, Boussion F, Saliou AH, Le Manac'h Dove G, Margaryan M, De Vries P, Sentilhes L, Levard G, Lardy H, Arnaud A, Leclair MD, Podevin G, Schmitt F. What prenatal ultrasound features are predictable of complex or vanishing gastroschisis? A retrospective study. *Prenat Diagn* 2017 **37**: 168–175.
  9. Andrade WS, Brizot ML, Rodrigues AS, Tannuri AC, Krebs VL, Nishie EN, Francisco RPV, Zugaib M. Sonographic markers in the prediction of fetal complex gastroschisis. *Fetal Diagn Ther* 2018; **43**: 45–52.
  10. D'Antonio F, Virgone C, Rizzo G, Khalil A, Baud D, Cohen-Overbeek TE, Kuleva M, Salomon LJ, Flacco ME, Manzoli L, Giuliani S. Prenatal risk factors and outcomes in gastroschisis: A Meta-analysis. *Pediatrics* 2015; **136**: e159–169.
  11. Robinson HP, Fleming JE. A critical evaluation of sonar crown rump length measurements. *Br J Obstet Gynaecol* 1975; **82**: 702–710.
  12. Snijders RJ, Nicolaides KH. Fetal biometry at 14–40 weeks' gestation. *Ultrasound Obstet Gynecol* 1994; **4**: 34–48.
  13. Nicolaides KH, Wright D, Syngelaki A, Wright A, Akolekar R. Fetal Medicine Foundation fetal and neonatal population weight charts. *Ultrasound Obstet Gynecol* 2018; **52**: 44–51.
  14. Goetzinger KR, Tuuli MG, Longman RE, Huster KM, Odibo AO, Cahill AG. Sonographic predictors of postnatal bowel atresia in fetal gastroschisis. *Ultrasound Obstet Gynecol* 2014; **43**: 420–425.
  15. Sherif Emil. Surgical strategies in complex gastroschisis. *Semin Pediatr Surg* 2018; **27**: 309–315.
  16. Osmundo Junior GS, Mohamed SHM, Nishie EN, Tannuri ACA, Gibelli MABC, Francisco RPV, Brizot ML. Association of spontaneous labor onset with neonatal outcomes in pregnancies with fetal gastroschisis: A retrospective cohort analysis. *Acta Obstet Gynecol Scand* 2019 **98**: 154–161.